

# Laser Treatment of Twin-to-Twin Transfusion Syndrome

Rubén A. Quintero,<sup>1,2</sup> Eftichia Kontopoulos,<sup>1,2</sup> and Ramen H. Chmait<sup>3</sup>

<sup>1</sup>Elizabeth J. Ferrell Fetal Health Center, Children's Mercy Hospital, Kansas City, Missouri, USA

<sup>2</sup>Division of Maternal-Fetal Medicine, Department of Obstetrics and Gynecology, Truman Medical Center, University of Missouri Kansas City, Kansas City, Missouri, USA

<sup>3</sup>Division of Maternal-Fetal Medicine, Department of Obstetrics and Gynecology, Keck School of Medicine, University of Southern California, Los Angeles, California, USA

**Objective:** Laser ablation of all placental vascular anastomoses is the optimal treatment for twin-twin transfusion syndrome (TTTS). However, two important controversies are apparent in the literature: (a) a gap between concept and performance, and (b) controversy regarding whether all the anastomoses can be identified endoscopically and whether blind lasering of healthy placenta is justified. The purpose of this article is: (a) to address the potential source of the gap between concept and performance by analyzing the fundamental steps needed to successfully accomplish the surgery, and (b) to discuss the resulting competency benchmarks reported with the different surgical techniques. **Materials and Methods:** Laser surgery for TTTS can be broken down into two fundamental steps: (1) endoscopic identification of the placental vascular anastomoses, (2) laser ablation of the anastomoses. The two steps are not synonymous: (a) regarding the endoscopic identification of the anastomoses, the non-selective technique is based upon lasering all vessels crossing the dividing membrane, whether anastomotic or not. The selective technique identifies and lasers only placental vascular anastomoses. The Solomon technique is based on the theory that not all anastomoses are endoscopically visible and thus involves lasering healthy areas of the placenta between lasered anastomoses, (b) regarding the actual laser ablation of the anastomoses, successful completion of the surgery (i.e., lasering all the anastomoses) can be measured by the rate of persistent or reverse TTTS (PRTTTS) and how often a selective technique can be achieved. Articles representing the different techniques are discussed. **Results:** The non-selective technique is associated with the lowest double survival rate (35%), compared with 60–75% of the Solomon or the Quintero selective techniques. The Solomon technique is associated with a 20% rate of residual patent placental vascular anastomoses, compared to 3.5–5% for the selective technique ( $p < .05$ ). Both the Solomon and the selective technique are associated with a 1% risk of PRTTTS. Adequate placental assessment is highest with the selective technique (99%) compared with the Solomon (80%) or the 'standard' (60%) techniques ( $p < .05$ ). A surgical performance index is proposed. **Conclusion:** The Quintero selective technique was associated with the highest rate of successful ablation and lowest rate of PRTTTS. The Solomon technique represents a historical backward movement in the identification of placental vascular anastomoses and is associated with higher rate of residual patent vascular communications. The reported outcomes of the Quintero selective technique do not lend support to the existence of invisible anastomoses or justify lasering healthy placental tissue.

■ **Keywords:** twin-twin transfusion syndrome, TTTS, laser therapy, fetal therapy

The treatment of TTTS has evolved through the years and has included expectant-medical management (Jones et al., 1993), *sectio parva* (Urig et al., 1988), serial amniocentesis (Dennis & Winkler, 1997; Saunders et al., 1992; Wax et al., 1991), and the current treatment using laser photocoagulation of the placental vascular anastomoses (De Lia et al., 1990; De Lia et al., 1995; Hecher et al., 2000; Quintero et al., 1998; Ville et al., 1992; Ville et al., 1995). The rationale for the use of laser photocoagulation in TTTS stems from the

RECEIVED 8 March 2016; ACCEPTED 10 March 2016.

ADDRESS FOR CORRESPONDENCE: Rubén A. Quintero, MD, Professor & Medical Director, Fetal Therapy, Elizabeth J. Ferrell Fetal Health Center, Children's Mercy Hospital, Department of Maternal-Fetal Medicine, 2401 Gillham Rd, Kansas City, MO 64108, USA. E-mail: raquintero@cmh.edu

fact that: (1) TTTS occurs via placental vascular anastomoses, which are responsible for the net imbalance sharing of blood volume between two (or more) fetuses; (b) as a corollary, TTTS does not occur in the absence of placental vascular anastomoses (e.g., dichorionic twins); (c) TTTS should disappear if the anastomoses are ablated.

Therefore, the goal of the laser surgery is to correctly identify and ablate all of the vascular anastomoses. This raises two issues: (1) can all of the placental vascular anastomoses be identified? (2) can all of the placental vascular anastomoses be ablated?

## Step 1: Identification of the Placental Vascular Anastomoses

Classic placental pathology studies have shown the presence of three different types of placental vascular anastomoses: arterio-venous (A-V; so-called 'deep anastomoses') and arterio-arterial (A-A) or veno-venous (V-V; so-called 'superficial') anastomoses (Benirschke & Kaufmann, 1995). All of these anastomoses can be seen on the surface of the placenta, even if the actual anastomotic exchange occurs deep within the substance of the placenta. While some authors have suggested that in fact there are anastomoses deep within the placental parenchyma that are not visible from the surface (Lewi et al., 2006), these surgical pathology arguments have been raised more to explain the failure of laser surgery from certain centers, rather than plausible surgical pathology explanations. In actuality, all of the different types of vascular anastomoses should be visible endoscopically from the fetal surface, with exceedingly few exceptions, provided obviously that they are within the reach of the endoscope.

How can the anastomoses be identified? In the early days of laser surgery, this was an issue of contention. The original reports suggested that the anastomoses could be identified based on their appearance, that is, based on specific patterns, angles, with drawings intended to aid in this process (identification based on pattern recognition; De Lia et al., 1993). Unfortunately, this was not conducive, given the myriad of patterns that the anastomoses can actually have. Furthermore, a pair of vessels could look exactly like an anastomosis, yet they could both trace back to the same fetus and thus not be an anastomosis. The lack of a practical way of identifying placental vascular anastomoses was one of the most important hindrances in the beginning of the era of laser surgery for TTTS. This led to the development of the so-called 'non-selective technique'.

### The Non-Selective Technique

The non-selective technique was based on lasering all of the vessels that would cross the dividing membrane. By definition, this technique did not attempt to differentiate anastomotic from non-anastomotic vessels, but rather to catch as many anastomoses as possible, based on three as-

sumptions: (1) the dividing membrane lies parallel to the vascular equator; (2) all of the vessels crossing the dividing membrane are vascular anastomoses; (3) the vascular anastomoses (vascular equator) are all within the sac of the recipient twin (where the endoscope is inserted).

In actuality, although many cases could fall within these three assumptions, the assumptions do not guarantee that only anastomotic vessels will be targeted. First, the location of the dividing membrane may or may not be parallel to the so-called vascular equator, the area of the placenta where the anastomoses are located. Indeed, the location of the dividing membrane relative to the fetal placental surface may be: (a) at an angle to the vascular equator (such that some of the anastomoses may be in the sac of the donor twin and some in the sac of the recipient twin); (b) completely within the sac of the donor twin, such that all of the anastomoses are inside the sac of the donor twin.

Second, and as a corollary, not all of the vessels crossing the dividing membrane are anastomotic vessels. Therefore, by lasering all of the vessels that would cross the dividing membrane, the risk of ablating normal vessels (i.e., non-anastomotic) could be high. Third, in the rare cases where all of the anastomoses are within the sac of the donor twin, lasering of all the vessels crossing the dividing membrane from within the sac of the recipient twin would aim only at recipient vessels (with or without anastomoses), with certain demise of this fetus. Clinical proof of the potential for harm to either twin from the use of a non-selective technique was shown in the report by Ville et al. (1995), where the use of the non-selective technique was associated with a dual fetal survival of only 35%, and a rate of single intrauterine fetal demise of 35% as well (Ville et al., 1995). Subsequent clinical studies showed that the use of a non-selective technique, which unnecessarily targeted vessels that were not involved in blood exchange between the fetuses, was associated with an increased risk for demise of one or both twins (Ville et al., 1995). Clearly, using the dividing membrane as a surrogate for the identification of the placental vascular anastomoses was suboptimal, albeit an improvement over the previously non-descriptive reports. Thus, a better way of identifying the actual anastomoses was needed.

### The Selective Technique

In 1998, Quintero et al. described the selective laser photocoagulation of communicating vessels technique (coined as 'SLPCV'; Quintero et al., 1998). This was the first description of a precise anatomical way of identifying the placental vascular anastomoses endoscopically and differentiating them from non-anastomotic vessels. The technique required a systematic assessment of the vascular equator from one end of the placenta to the other. Basically, this meant following each and every vessel on the surface of the placenta to its terminal end. If the terminal end of an artery of one twin was accompanied by a returning vein

to the same fetus, this was labeled as a non-anastomotic pair. On the other hand, if the terminal end of an artery was accompanied by a returning vein to the other twin, this was labeled as an A-V anastomosis. A-A anastomoses were apparent, since the artery of one twin would continue as an artery to the other twin. Similarly, V-V anastomoses could be identified by following a vein from one twin to the other. The identification of these anastomoses did not rely on the location of the dividing membrane on the surface of the placenta. This avoided missing anastomoses located in the sac of the donor, whether this meant a few or even all of the anastomoses. Visualization of the anastomoses through the dividing membrane within the sac of the donor was also shown to be possible. This was in contrast to previous reports, where presumably the anastomoses within the sac of the donor were not visible due to the presence of two layers of amnion (De Lia et al., 1993). In fact, the two layers of amnion do not preclude visualization of the anastomoses within the sac of the donor twin, particularly when there is severe oligohydramnios or anhydramnios in the sac of that fetus. The selective technique provided a reproducible way of identifying all of the vascular anastomoses, independent of their location, a first step in the proper performance of the laser surgical technique. R. Quintero, L. Quintero L., (2000) also reported how to document the vascular anastomoses. This included mentioning the size (hair, small, medium, large, extra-large) of the anastomoses, as well as their direction (from donor to recipient or from recipient to donor). The direction of flow in A-A or V-V anastomoses cannot be determined in most cases, unless significant discoloration is present in these vessels from differences in fetal SpO<sub>2</sub> (Quintero et al., 2008). In cases with significant discoloration differences, the collision front between the two fetal circulations within an A-A or a V-V anastomosis led to the concept of the 'hemodynamic equator' (HE; Chang et al., 2006). The HE allowed, for the first time, a better understanding of the actual behavior of A-A or V-V anastomoses, which until then were thought to be bidirectional in all cases. Indeed, if the HE moves back and forth between draining vessels of either twin, the behavior of the A-A or V-V anastomosis is truly bidirectional. On the other hand, if the HE only reaches a draining vessel of one twin, the function of the superficial vessel is essentially no different than an AV anastomosis (and, as such, labeled as fAVDR if from donor to recipient, or fAVRD if from recipient to donor). Lastly, if the HE does not reach any draining vessel, the net exchange of blood between the fetuses through that vessel is zero.

The selective technique also assumed that once the vascular equator was entirely mapped, the anastomoses could all be photocoagulated (a two-step process).

The acronym used for the selective technique, that is, SLPCV, defined the systematic approach that needs to take place to identify and photocoagulate all of the vascular anastomoses. Other acronyms used to describe the performance of the laser surgery may or may not be similar

**TABLE 1**

**Reported Incidence of Residual Patent Placental Vascular Anastomoses After Laser Surgery on Surgical Pathology Analysis of the Placentas. Comparisons Made Relative to the Lowest Reported Rate (P1) or Between the 'Standard' and the Solomon Techniques (P2)**

| Author   | Residual patent placental vascular anastomoses | P1     | P2    |
|--|--|--------|-------|
| Quintero et al. (2010), SLPCV                    | 5/143 (3.5%)                                   | –      |       |
| Chmait et al. (2010), SLPCV                      | 5/100 (5%)                                     | 0.74   |       |
| Lopriore et al. (2007), Fetoscopic laser surgery | 17/52 (33%)                                    | <0.001 |       |
| Slaghekke, Lopriore et al. (2014)                |  |        |       |
| 'Standard'                                       | 26/77 (34%)                                    | <0.001 | >0.05 |
| Solomon  | 14/74 (19%)                                    | <0.001 |       |

to the Quintero SLPCV technique. For example, while performing SLPCV, the dividing membrane is always respected. Purposeful injury to the dividing membrane, or so-called 'septostomy', is not part of the SLPCV technique (Harkness & Crombleholme, 2005). Though not implicit, the performance of a laparotomy to access the amniotic cavity is also not part of the SLPCV technique. While general anesthesia was originally used in our cases (Rossi et al., 2008), surgery can be best performed under local anesthesia (Ville et al., 1998). Therefore, the acronym SLPCV should apply only to those surgeries in which access to the amniotic cavity is performed under local anesthesia, percutaneously, and following a systematic and thorough identification and obliteration only of placental vascular anastomoses (Chmait et al., 2011; Quintero, 2002; Quintero et al., 1998).

### Connecting the Dots: The 'Solomon' Technique

As other centers began to adopt the selective technique, one particular issue of concern became apparent. Indeed, the reported incidence of residual patent placental vascular anastomoses after laser surgery on surgical pathology analysis of the placentas varied significantly between centers (Table 1). Similarly, the incidence of failed surgery, defined as PRTTTS, which is the clinical manifestation of residual patent placental vascular anastomoses after laser surgery, also varied significantly (Table 2). In a study by Robyr et al. (2006), the rate of failed surgery was 22%. Anemia after demise of one of the fetuses was also noted as a complication, which is indirect evidence of residual patent placental vascular anastomoses as well. Lopriore et al. (2006) reported an incidence of 33% of residual patent placental vascular anastomoses in 52 TTTS patients treated with laser at their institution. In comparison, the rate of residual patent placental vascular anastomoses after SLPCV by our group, using similar technique and technology, has

**TABLE 2**

**Reported Incidence of Clinical Outcomes After Laser Therapy Reflecting Residual Patent Placental Vascular Anastomoses. Comparisons Made Relative to the Lowest Reported Rate**

| Author                            | Reverse or persistent TTTS | <i>p</i> |
|-----------------------------------|----------------------------|----------|
| Chmait et al. (2010)              | 1/100 (1%)                 | –        |
| Kontopoulos et al. (2015)         | 5/417 (1.5%)               | 1.0      |
| Robyr et al. (2006)               | 14/101 (13.8%)             | .0006    |
| Lopriore et al. (2006)            | 2/52 (3.8%)                | .27      |
| Slaghekke, Lopriore et al. (2014) |                            |          |
| ‘Standard’                        | 9/135 (6.7%)               | .046     |
| Solomon                           | 2/137 (1.5%)               | 1.0      |
| Baschat et al. (2013)             |                            |          |
| ‘Selective’                       | 6/71 (8.5%)                | .02      |
| Solomon                           | 3/76 (3.9%)                | .31      |
| Ruano et al. (2013)               |                            |          |
| ‘Selective’                       | 4/76 (5.3%)                | .17      |
| Solomon                           | 0/26 (0%)                  | 1        |

consistently been less than 5%, with no anemia after demise of the co-twin, and an incidence of reverse or persistent TTTS of only 1–1.5% (USFetus Consortium; Quintero, 2007).

In view of the relatively high incidence of residual patent placental vascular anastomoses seen by some groups, some authors proposed ‘connecting the dots’ between photocoagulated areas on the surface of the placenta (Chalouhi et al., 2011). The premise behind this idea was that by laser-ing areas between laser-ablated placental vascular anastomoses, such ‘blind laser-ing’ would capture ‘anastomoses’ that would otherwise be missed (i.e., ‘not visible’; Lewi et al., 2006). Such authors believed that, in fact, not all of the placental vascular anastomoses can be identified endoscopically (Lewi et al., 2006), and that therefore, ablating only the visible ones using the selective technique could miss vascular anastomoses and explain their high rate of residual patent placental vascular anastomoses. The resulting surgical technique of ‘connecting the dots’ was dubbed ‘the Solomon technique’ (Chalouhi et al., 2011), in reference to the biblical passage where, in order to resolve a dispute between two alleging mothers of a child, King Solomon proposed to cut the baby in half (1 Kings 3:16–28, NIV). The analogy, therefore, is that by laser-ing the areas of the placenta between endoscopically identified and laser-ablated vascular anastomoses, the placenta would be ‘cut in half’. Recent studies suggest that indeed, relative to the surgical groups’ prior experience with the selective technique, the use of the Solomon technique was associated with improved perinatal outcomes (Baschat et al., 2013; Ruano et al., 2013).

To test whether the Solomon technique could indeed reduce the rate of residual patent placental vascular anastomoses, an open-label randomized clinical trial was conducted in Europe (the Solomon trial) comparing the Solomon technique with the ‘standard’ technique (Slaghekke, Lopriore et al., 2014). The latter, although not directly mentioned, was intended to refer to the selective

technique (SLPCV). Interestingly, the actual rate of persistent residual patent placental vascular anastomoses was no different between the two techniques (14/74, 19% vs. 23/77, 29.8%, Solomon vs. ‘standard’, respectively,  $p = .12$ ). However, the study did show a decreased rate of PRTTTS (2/137, 1% vs. 9/135, 7%, Solomon vs. ‘standard’, respectively,  $p = .03$ ) and of twin-anemia-polycythemia syndrome (TAPS; 4/137, 2.9% vs. 21/135, 15.5%, Solomon vs. ‘standard’, respectively,  $p = < .001$ ). Although the rationale and primary outcome of the study (to reduce the rate of residual patent placental vascular anastomoses) was no different between the groups, the authors concluded that the Solomon technique was superior to the ‘standard’ technique. Two additional observational studies comparing the Solomon technique with the selective technique also appeared to show favorable results with the former technique (Baschat et al., 2013; Ruano et al., 2013).

Table 1 shows the rate of residual patent placental vascular anastomoses reported by the different groups using either the Quintero selective (SLPCV) technique, or the ‘standard’ or the Solomon technique in the Solomon trial. As can be seen, the rate of residual patent placental vascular anastomoses is lowest using the Quintero SLPCV versus the ‘standard’ or Solomon techniques. Table 2 shows that the Quintero SLPCV technique is also associated with a lower rate of PRTTTS than that of the ‘standard’ technique in the Solomon trial and the ‘selective technique’ of other authors, and that the Solomon technique in all studies achieves the same rate of PRTTTS than that reported with Quintero SLPCV. Given that the Solomon technique is still associated with approximately 20% of residual patent placental vascular anastomoses, the initial rationale for the technique, that is, to reduce the high rate of residual patent placental vascular anastomoses, does not appear to hold. Furthermore, given that the proponents of the Solomon technique have also shown that most missed anastomoses are located in the margins of the placenta (Lopriore et al., 2006), laser-ing inexistent placental vascular anastomoses in otherwise healthy placental tissue between vascular anastomoses within the main body of the placenta is incongruent with the rationale (Table 3, Figure 1(a) and (b)). Altogether, the Solomon technique would seem to represent a step backwards in the ability to correctly identify all of the placental vascular anastomoses, by accepting the unproven theory of the presence of non-visible placental vascular anastomoses on the otherwise healthy appearing fetal surface of the placenta. Alternatively, we have shown that *all* of the placental vascular anastomoses can be clearly identified without having to ablate inexistent anastomoses in healthy placental areas. Stated differently, the use of the Solomon technique may simply represent an approach to achieving similar results as those that can be obtained with the performance of the Quintero SLPCV technique, rather than a true advantage over the SLPCV technique, at the expense of laser-ing healthy placental tissue.

TABLE 3

Principles and Results of the Use of the Solomon Technique to Identify and Ablate All Placental Vascular Anastomoses in Twin–Twin Transfusion Syndrome

| Purpose of the surgery:  | Purported location of the residual patent placental vascular anastomoses: | Actual location of the additional laser ablations:                                      | Rate of residual patent placental vascular anastomoses (Slaghekke, Lopriore et al., 2014): | Rate of residual patent placental vascular anastomoses (USFetus group) (Chmait et al., 2010; R. A. Quintero et al., 2010): |
|--|---|---|--|--|
| To decrease the rate of residual patent placental vascular anastomoses after laser therapy | Mostly on the margins of the placenta                                     | Within the body of the placenta, between endoscopically identified vascular anastomoses | 30% ('Standard' vs. 19% (Solomon) $p > .05$ )  | 5%<br>$p < .05$ relative to Solomon technique  |

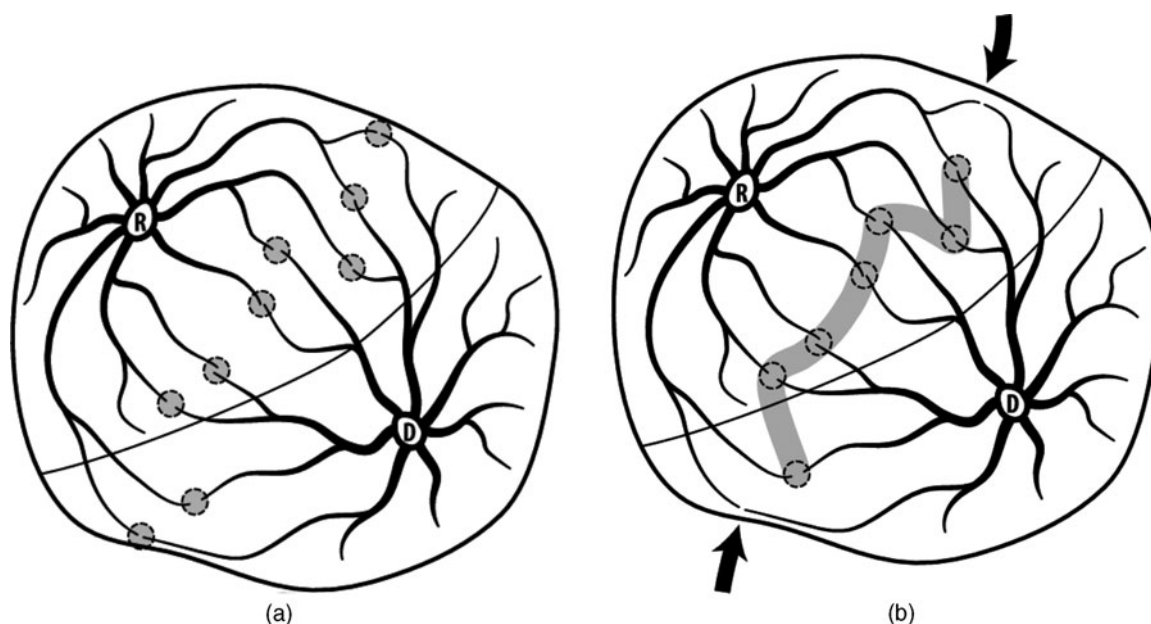


FIGURE 1

(a). Selective photocoagulation of communicating vessels (SLPCV). All of the anastomoses are photocoagulated, regardless of their location relative to the dividing membrane, while sparing non-anastomotic vessels. Rate of residual patent placental vascular anastomoses: 3.5–5%. (Chmait et al., 2010; Kontopoulos et al., 2015). (b) Solomon modification of the SLPCV technique. The fetal surface of the placenta between endoscopically identified anastomoses is also lasered, to occlude 'anastomoses' not visible by the endoscope. Note that marginal anastomoses may be missed, as they are not between laser shots. Rate of residual patent vascular anastomoses: 20% (Slaghekke, Lopriore et al., 2014).

## Step Two: Ablation of the Placental Vascular Anastomoses

Assuming that there is a conceptual agreement on how to identify the anastomoses, the next step consists of being able to ablate them. Successful ablation of the placental vascular anastomoses assumes that the surgeon can adapt to the different clinical scenarios and overcome the various challenges that may be present in each case. Particular known surgical challenges include:

1. the location of the placenta (anterior, posterior);
2. interference with the visualization of the anastomoses by the donor twin that is 'stuck' along the vascular equator from severe oligohydramnios (unmovable donor);
3. the presence of discolored fluid within the sac of the recipient twin from prior procedures (amniocenteses) or from prior intra-amniotic bleeding;
4. triplet (or higher order multiple) gestations, whether monochorionic or not;
5. close proximity of the umbilical cord placental insertions;
6. large anastomotic vessels;
7. tangential access to the placenta (whether the placenta is anterior or posterior);
8. anastomoses located behind the entry of the trocar;
9. high maternal BMI.

The management of each of these challenges requires the use of special techniques or technology, including the use of

fluid management systems, blunt probes, trocar assistance (Quintero et al., 2010), and special laser photocoagulation techniques, which are beyond the scope of this article (Quintero, 2007). A recent Delphi study outlined the multitude of steps needed to perform the surgery. Most authors agreed on the basic surgical goal (the purpose of the Delphi survey), including the ablation of all of the placental vascular anastomoses along the vascular equator, without injuring healthy placenta or non-anastomotic vessels (Peeters et al., 2015). The question is: How often can these goals be accomplished while overcoming the various challenges mentioned above? One way to address this question is by noting both how often the placenta can be adequately assessed, as well as how often the vessels can be selectively ablated.

### Adequate Placental Assessment

Adequate placental assessment refers to the ability of the surgeon to survey the entire vascular equator. For example, in a subanalysis of the Solomon trial, the authors reported that they were able to adequately assess the placenta in only 65 out of 74 patients in the Solomon group (87%) compared to also only 69 out of 77 (89%) in the 'standard' group (Slaghekke, Lewi et al., 2014). The reasons behind the inability of the surgeons to adequately assess the placenta in more than 10% of the cases in each group were not stated. Obviously, if the placenta cannot be adequately assessed, this may result in missing anastomoses and thus an increased likelihood for adverse clinical outcomes, including PRTTTS. In contrast, our group has shown consistently the ability to assess the placenta adequately in over 99% of the patients (Crisan et al., 2010).

### Selective Ablation of the Anastomoses

Another surgical competency benchmark refers to the ability of the surgeon to selectively ablate the vascular anastomoses without including non-anastomotic vessels. A 'selectivity index' (SI) was proposed by Stirnemann et al. (2008), as  $SI = \log(SC + 1) / (NSC + 1)$ , where SC are the selectively coagulated vessels and NSC are the non-anastomotic vessels. NSC were also vessels that were considered presumed anastomoses, but that could not be followed to their terminal end and were nonetheless lasered. In their experience, most surgeries involved lasering both anastomotic and non-anastomotic vessels (Chalouhi et al., 2011; Stirnemann et al., 2008). A 'high' SI, defined as  $>0.25$ , was reported by the authors to correlate with improved postnatal survival at 28 days of at least one twin and both twins. Crisan et al. (2010) have shown that such an index is mathematically inaccurate and should not be used to assess the adequacy of the laser surgery. Instead, a simpler index consisting of a ratio between how often the surgery can be done using the Quintero selective technique versus non-selectively, is more representative and easier to understand:  $(QSI = 100 * \frac{SLPCV - NSLPCV}{SLPCV})$ , where QSI is the Quintero SI, SLPCV is a surgery performed selectively, NSLPCV is a

surgery where at least one vessel was not clearly identified as an anastomosis but was lasered. For example, in that same article, the authors showed that they were able to perform a selective surgery in only 34% of cases (Stirnemann et al., 2008). In another report of 123 patients, surgery could not be completed in five cases for a stuck twin obscuring the equator (2), poor visualization (2) and a large anastomotic vessel (1) (Lopriore et al., 2006). Obviously, the goal is to try to perform the surgery selectively as close to 100% of the time as possible (Chmait et al., 2011; Crisan et al., 2010; Kontopoulos et al., 2015).

### Accuracy of Laser Therapy

Theoretically, one could combine the rate of adequate placental assessment and of selective laser surgery with the rate of either residual patent placental vascular anastomoses (when available) and the rate of PRTTTS to determine how accurate the laser surgery is being performed at a given center or by a given surgeon. Accuracy of SLPCV could thus be defined as:

$$\text{AccSLPCV} = \text{QSI} * (1 - \text{RPPVA}) * (1 - \text{PRTTTS}),$$

where AccSLPCV is the accuracy in performing SLPCV, QSI is the rate of Quintero selectively performed surgeries, RPPVA is the rate of residual patent placental vascular anastomoses (when available) and PRTTTS is the rate of PRTTTS. Table 4 shows such a theoretical calculation and its use to compare different reports.

### Should the Rate of TAPS be Included as a Benchmark for the Performance of Laser Therapy in TTTS?

The rate of TAPS has been included as a measure of failed laser therapy for TTTS, in addition to the rate of residual patent placental vascular anastomoses and persistent/reverse TTTS (Baschat et al., 2013; Chmait et al., 2010; Ruano et al., 2013; Slaghekke, Lewi, et al., 2014; Slaghekke, Lopriore, et al., 2014). The decision stems from the purported etiology of TAPS, which presumably results from the transfer of blood between two monochorionic twins through small placental vascular anastomoses in such a way that one fetus develops anemia and the other twin develops polycythemia, but without the net blood volume inequalities typical of TTTS (Lopriore et al., 2007). Presumably, the syndrome occurs through small caliber AV anastomoses, in contrast to larger size vessels typically seen in TTTS. In actuality, such a theory is even less plausible than the contested theory of TTTS (in which all indirect and circumstantial evidence does point to placental vascular anastomoses as being the etiological factor for TTTS, and indirectly confirmed by resolution of the syndrome with occlusion of all placental vascular anastomoses). The proposed theory of TAPS is thus suspect for many reasons:

1. the original theory was based on the presence of residual patent placental vascular anastomoses. Given the high

**TABLE 4**  
Accuracy of Laser Surgery for Twin–Twin Transfusion Syndrome

| Author  | Rate of selectively performed surgeries | 1 – rate of residual patent placental vascular anastomoses | 1 – rate of persistent/reverse TTTS | Accuracy of SLPCV |
|---|---|--|-------------------------------------|-------------------|
| USFetus group (Crisan et al., 2010; Kontopoulos et al., 2015) | 98.7%                                   | 0.95   | 0.99                                | 92%               |
| Solomon (Slaghekke, Lopriore et al., 2014)                    | 87%                                     | 0.81   | 0.99                                | 69.7%             |
| Solomon (Slaghekke, Lopriore et al., 2014) ‘standard’         | 89%                                     | 0.66   | 0.93                                | 54%               |

**TABLE 5**  
Role of Placental Vascular Anastomoses in the Etiology of Twin–Twin Transfusion Syndrome and Twin-Anemia-Polycythemia Syndrome

|  | TTTS | TAPS   |
|--|------|--|
| Can exist in the presence of placental vascular anastomoses  | Yes  | Yes  |
| Can exist in the absence of placental vascular anastomoses   | No   | Yes (Kontopoulos et al., 2015; Taniguchi et al., 2015) |
| Is eliminated by ablating the placental vascular anastomoses | Yes  | ? (Slaghekke, Favre, et al., 2014)                     |

Note: TTTS = twin–twin transfusion syndrome; TAPS = twin-anemia-polycythemia syndrome.

incidence of residual patent placental vascular anastomoses reported from such groups (20–33%), it is not possible to discern what role, if any, these anastomoses play in the etiology of TAPS.

- while TAPS has been described in the presence of residual patent placental vascular anastomoses, they are not indispensable. We and others have recently reported on the presence of TAPS without apparent placental vascular anastomoses (Kontopoulos et al., 2015; Taniguchi et al., 2015).
- contrary to TTTS, ablation of residual patent placental anastomoses in cases of TAPS does not necessarily eliminate the condition. Table 5 compares TTTS with TAPS relative to the role of placental vascular anastomoses.

Therefore, at this point, the assumption that TAPS is the result of unsuccessful laser therapy constitutes a leap of faith in the understanding of both the etiology of TAPS and the role that laser therapy may play in the occurrence of this condition. In our opinion, the inclusion of TAPS as a benchmark of failed laser therapy should be reconsidered.

### Functional Ablation of the Placental Vascular Anastomoses: The Sequential Technique

The development of the selective technique represents an important historical step in the surgical treatment of TTTS.

SLPCV is indeed an anatomical surgical technique, which involves the identification and selective laser obliteration of the placental vascular anastomoses. However, intrauterine fetal demise of one of the two fetuses after SLPCV would still occur in approximately 9–29% of cases with this technique (Quintero et al., 1998; R. Quintero, C. Comas, 2000). Because TTTS presumably occurs from an excessive transfer of blood from the donor twin to the recipient twin, the sequence with which the anastomoses are obliterated during surgery could have prognostic implications. Indeed, if the anastomoses from the donor to the recipient are obliterated first, that would immediately stop the transfer of blood from this twin to the recipient. Furthermore, during this interval, however brief, the recipient twin would be transfusing the donor twin back. As a result, the donor twin, which is presumably hypotensive, would stop losing blood as soon as the laser process starts, while at the same time would start receiving additional blood back from the recipient twin. The photocoagulation of the vascular anastomoses from donor-to-recipient first, followed by from recipient-to-donor second was called the ‘sequential technique’ or SQLPCV. Using a sequential technique, our group showed a reduction in the rate of intrauterine fetal demise of the donor twin from 21% to 7%, and an increase in the double survival rate from 56% to 75% (Quintero et al., 2007). Our group is currently assessing the merits of performing a sequential technique through a randomized clinical trial of the USFetus group (Chmait et al., 2014). While a sequential technique may not necessarily be required in all cases, it could have an indication in patients where the condition of the donor twin would be most compromised.

### Is There a Role for Umbilical Cord Occlusion in TTTS?

Interruption of the blood exchange between the fetuses can also be accomplished by occluding one of the two umbilical cords. This procedure should be contemplated only as a last resort to treat the syndrome. Unfortunately, the availability of bipolar photocoagulation and radiofrequency ablation has resulted in an unwarranted number of selective feticide in patients that otherwise could have perhaps been treated best with laser surgery (Chalouhi et al., 2010; Chalouhi

et al., 2011). Umbilical cord occlusion should not be offered as an alternative to laser because of limitations of the surgeon or the center, unless the patient cannot be referred to another center capable of offering laser. Umbilical cord occlusion should be offered to patients with TTTS in which additional complicating circumstances may exist. This may be the case of patients with a severe congenital anomaly of one of the twins, or a moribund hydropic fetus. Since such cases are rare, the performance of selective feticide via umbilical cord occlusion in TTTS should be an exception, rather than the rule. Indeed, the counseling of our patients involves mentioning a survival rate of approximately 90% with a 5% risk of neurological damage if laser therapy is chosen, compared to 90% survival and a 5% risk of neurological damage to the surviving co-twin if umbilical cord occlusion is chosen. Therefore, since both survival and morbidity statistics are similar between the two procedures, but with umbilical cord occlusion one of the fetuses is denied the chance to survive, the justification is not there to offer feticide to an otherwise anatomically normal fetus.

## Conclusion

It has been more than 20 years since laser therapy was first proposed for the treatment of TTTS. Significant strides have been made both in establishing the scientific merit of using laser to ablate the placental vascular anastomoses to treat the condition (Senat et al., 2004) as well as in the various steps, techniques, and other technical aspects that allow such therapy. Selectively interrupting the placental vascular anastomoses without injuring healthy portions of the placenta using the Quintero selective technique, while obvious as a concept and as a surgical goal, has been associated with markedly different outcome results between centers. The Solomon technique has been proposed as a way to mitigate such differences, but has not shown to lower the high rate of residual patent placental vascular anastomoses that prompted its development. A properly performed Quintero SLPCV technique is associated with the highest rate of clinical success and with the lowest rate of failed therapy either by surgical pathology or clinical criteria. Further improvements in clinical outcomes with the use of the sequential technique, particularly for specific situations in which the donor may be at a unique disadvantage, could be expected and is being addressed in the ongoing randomized clinical trial conducted by our groups comparing SLPCV with SQLPCV. Selective feticide via umbilical cord occlusion should be the exception rather than the rule for severe cases of TTTS, and should not be performed to compensate for physician or surgical center limitations. Improvements in the surgical equipment and other ancillary technology, while difficult to pursue, should continue to remain among the objectives of caregivers in this field. The education of the next generation of surgeons using the wealth of information

thus far gathered by the different centers should also be a main focus of all programs.

## References

- Baschat, A. A., Barber, J., Pedersen, N., Turan, O. M., & Harman, C. R. (2013). Outcome after fetoscopic selective laser ablation of placental anastomoses versus equatorial laser dichorionization for the treatment of twin-to-twin transfusion syndrome. *American Journal of Obstetrics and Gynecology*, 209, 234.e1–e8.
- Benirschke, K., & Kaufmann, P. (1995). *Pathology of human placenta*. New York: Springer-Verlag.
- Chalouhi, G. E., Essaoui, M., Stirnemann, J., Quibel, T., Deloison, B., Salomon, L., & Ville, Y. (2011). Laser therapy for twin-to-twin transfusion syndrome (TTTS). *Prenatal Diagnosis*, 31, 637–646.
- Chalouhi, G. E., Stirnemann, J. J., Salomon, L. J., Essaoui, M., Quibel, T., & Ville, Y. (2010). Specific complications of monochorionic twin pregnancies: Twin-twin transfusion syndrome and twin reversed arterial perfusion sequence. *Seminars in Fetal and Neonatal Medicine*, 15, 349–356.
- Chang, Y. L., Chmait, R. H., Bornick, P. W., Allen, M. H., & Quintero, R. A. (2006). The role of laser surgery in dissecting the etiology of absent or reverse end-diastolic velocity in the umbilical artery of the donor twin in twin-twin transfusion syndrome. *American Journal of Obstetrics and Gynecology*, 195, 478–483.
- Chmait, R. H., Assaf, S. A., & Benirschke, K. (2010). Residual vascular communications in twin-twin transfusion syndrome treated with sequential laser surgery: Frequency and clinical implications. *Placenta*, 31, 611–614.
- Chmait, R. H., Kontopoulos, E. V., Korst, L. M., Llanes, A., Petisco, I., & Quintero, R. A. (2011). Stage-based outcomes of 682 consecutive cases of twin-twin transfusion syndrome treated with laser surgery: The USFetus experience. *American Journal of Obstetrics and Gynecology*, 204, e391–e396.
- Chmait, R. H., Kontopoulos, E. V., & Quintero, R. A. (2014). Sequential laser surgery for twin-twin transfusion syndrome. *American Journal of Perinatology*, 31(Suppl. 1), S13–S18.
- Crisan, L. S., Kontopoulos, E. V., & Quintero, R. A. (2010). Appraisal of the selectivity index in a cohort of patients treated with laser surgery for twin-twin transfusion syndrome. *American Journal of Obstetrics and Gynecology*, 202, 157 e151–e155.
- De Lia, J. E., Kuhlmann, R. S., Cruikshank, D. P., & O’Bee, L. R. (1993). Current topic: Placental surgery: A new frontier. *Placenta*, 14, 477–485.
- De Lia, J. E., Cruikshank, D. P., & Keye, W. R. Jr. (1990). Fetoscopic neodymium: YAG laser occlusion of placental vessels in severe twin-twin transfusion syndrome. *Obstetrics & Gynecology*, 75, 1046–1053.
- De Lia, J. E., Kuhlmann, R. S., Harstad, T. W., & Cruikshank, D. P. (1995). Fetoscopic laser ablation of placental vessels in severe previable twin-twin transfusion syndrome. *American*



- Journal of Obstetrics and Gynecology*, 172(4 Pt 1), 1202–1208, discussion 1208–1211.
- Dennis, L. G., & Winkler, C. L. (1997). Twin-to-twin transfusion syndrome: Aggressive therapeutic amniocentesis. *American Journal of Obstetrics and Gynecology*, 177, 342–347, discussion 347–349.
- Harkness, U. F., & Crombleholme, T. M. (2005). Twin-twin transfusion syndrome: Where do we go from here? *Seminars in Perinatology*, 29, 296–304.
- Hecher, K., Diehl, W., Zikulinig, L., Vetter, M., & Hackeloer, B. J. (2000). Endoscopic laser coagulation of placental anastomoses in 200 pregnancies with severe mid-trimester twin-to-twin transfusion syndrome. *European Journal of Obstetrics & Gynecology and Reproductive Biology*, 92, 135–139.
- Jones, J., Sbarra, A., Dilillo, L., Cetrulo, C. L., & D'Alton, M. E. (1993). Indomethacin in severe twin-to-twin transfusion syndrome. *American Journal of Perinatology* 10, 24–26.
- Kontopoulos, E., Chmait, R., Baker, B., Llanes, A., & Quintero, R. (2015). USFetus surgical benchmarks of selective laser therapy for twin-twin transfusion syndrome. *American Journal of Obstetrics and Gynecology*, 212, S91–S92.
- Lewi, L., Jani, J., Cannie, M., Robyr, R., Ville, Y., Hecher, K., . . . Deprest, J. (2006). Intertwin anastomoses in monochorionic placentas after fetoscopic laser coagulation for twin-to-twin transfusion syndrome: Is there more than meets the eye? *American Journal of Obstetrics and Gynecology*, 194, 790–795.
- Lopriore, E., Middeldorp, J. M., Oepkes, D., Kanhai, H. H., Walther, F. J., & Vandenbussche, F. P. (2007). Twin anemia-polycythemia sequence in two monochorionic twin pairs without oligo-polyhydramnios sequence. *Placenta*, 28, 47–51.
- Lopriore, E., Middeldorp, J. M., Oepkes, D., Klumper, F. J., Walther, F. J., & Vandenbussche, F. P. (2006). Residual anastomoses after fetoscopic laser surgery in twin-to-twin transfusion syndrome: Frequency, associated risks and outcome. *Placenta*, 28, 204–208.
- Peeters, S. H., Akkermans, J., Westra, M., Lopriore, E., Middeldorp, J. M., Klumper, F. J., . . . Oepkes, D. (2015). Identification of essential steps in laser procedure for twin-twin transfusion syndrome using the Delphi methodology: SILICONE study. *Ultrasound in Obstetrics and Gynecology*, 45, 439–446.
- Quintero, R. (2002). Selective laser photocoagulation of communicating vessels in twin-twin transfusion syndrome. In R. Quintero (Ed.), *Diagnostic and operative fetoscopy*. (pp. 43–54). New York: The Parthenon Publishing Group.
- Quintero, R. (2007). Laser treatment for twin-twin transfusion syndrome. In R. Quintero (Ed.), *Twin-twin transfusion syndrome*. (pp. 99–120). London: Informahealth.
- Quintero, R., Morales, W., Mendoza, G., Allen, M., Kalter, C., Giannina, G., & Angel, J. (1998). Selective photocoagulation of placental vessels in twin-twin transfusion syndrome: Evolution of a surgical technique. *Obstetrical and Gynecological Survey*, 53, s97–s103.
- Quintero, R., Quintero, L., Pivatelli, A., Bornick, P., Allen, M., & Johnson, P. (2000). The donor-recipient (D-R) score: In vivo endoscopic evidence to support the hypothesis of a net transfer of blood from donor to recipient in twin-twin transfusion syndrome. *Prenatal and Neonatal Medicine*, 5, 84–91.
- Quintero, R. A., Chmait, R. H., Bornick, P. W., & Kontopoulos, E. V. (2010). Trocar-assisted selective laser photocoagulation of communicating vessels: A technique for the laser treatment of patients with twin-twin transfusion syndrome with inaccessible anterior placentas. *Journal of Maternal-Fetal and Neonatal Medicine*, 23, 330–334.
- Quintero, R. A., Chmait, R. H., Carver, J., Bornick, P. W., Allen, M. H., & Kontopoulos, E. V. (2008). In utero fetal oximetry via visible light spectroscopy in twin-twin transfusion syndrome. *American Journal of Obstetrics and Gynecology*, 199, 639.e1–e4.
- Quintero, R. A., Comas, C., Bornick, P. W., Allen, M. H., & Kruger, M. (2000). Selective versus non-selective laser photocoagulation of placental vessels in twin-twin transfusion syndrome. *Ultrasound in Obstetrics and Gynecology*, 16, 230–236.
- Quintero, R. A., Ishii, K., Chmait, R. H., Bornick, P. W., Allen, M. H., & Kontopoulos, E. V. (2007). Sequential selective laser photocoagulation of communicating vessels in twin-twin transfusion syndrome. *Journal of Maternal-Fetal and Neonatal Medicine*, 20, 763–768.
- Robyr, R., Lewi, L., Salomon, L. J., Yamamoto, M., Bernard, J. P., Deprest, J., & Ville, Y. (2006). Prevalence and management of late fetal complications following successful selective laser coagulation of chorionic plate anastomoses in twin-to-twin transfusion syndrome. *American Journal of Obstetrics and Gynecology*, 194, 796–803.
- Rossi, A. C., Kaufman, M. A., Bornick, P. W., & Quintero, R. A. (2008). General versus local anesthesia for the percutaneous laser treatment of twin-twin transfusion syndrome. *American Journal of Obstetrics and Gynecology*, 199, 137.e1–e7.
- Ruano, R., Rodo, C., Peiro, J. L., Shamshirsaz, A., Haeri, S., Nomura, M. L., . . . Belfort, M. A. (2013). Fetoscopic laser ablation of the placental anastomoses in twin-twin transfusion syndrome using the 'Solomon technique'. *Ultrasound in Obstetrics and Gynecology*, 42, 434–439.
- Saunders, N. J., Snijders, R. J., & Nicolaides, K. H. (1992). Therapeutic amniocentesis in twin-twin transfusion syndrome appearing in the second trimester of pregnancy. *American Journal of Obstetrics and Gynecology*, 166, 820–824.
- Senat, M. V., Deprest, J., Boulvain, M., Paupe, A., Winer, N., & Ville, Y. (2004). Endoscopic laser surgery versus serial amnioreduction for severe twin-to-twin transfusion syndrome. *New England Journal of Medicine*, 351, 136–144.
- Slaghekke, F., Favre, R., Peeters, S. H., Middeldorp, J. M., Weingertner, A. S., van Zwet, E. W., . . . Lopriore, E. (2014). Laser surgery as a management option for twin anemia-polycythemia sequence. *Ultrasound in Obstetrics and Gynecology*, 44, 304–310.
- Slaghekke, F., Lewi, L., Middeldorp, J. M., Weingertner, A. S., Klumper, F. J., Dekoninck, P., . . . Lopriore, E. (2014). Residual anastomoses in twin-twin transfusion syndrome after laser: The Solomon randomized trial. *American Journal of Obstetrics and Gynecology*, 211, 285.e1–e7.

- Slaghekke, F., Lopriore, E., Lewi, L., Middeldorp, J. M., van Zwet, E. W., Weingertner, A. S., . . . Oepkes, D. (2014). Fetoscopic laser coagulation of the vascular equator versus selective coagulation for twin-to-twin transfusion syndrome: An open-label randomised controlled trial. *Lancet*, 383, 2144–2151.
- Stirnemann, J. J., Nasr, B., Quarello, E., Ortqvist, L., Nassar, M., Bernard, J. P., & Ville, Y. (2008). A definition of selectivity in laser coagulation of chorionic plate anastomoses in twin-to-twin transfusion syndrome and its relationship to perinatal outcome. *American Journal of Obstetrics and Gynecology*, 198, 62e61–e66.
- Taniguchi, K., Sumie, M., Sugibayashi, R., Wada, S., Matsuoka, K., & Sago, H. (2015). Twin anemia-polycythemia sequence after laser surgery for twin-twin transfusion syndrome and maternal morbidity. *Fetal Diagnosis and Therapy*, 37, 148–153.
- Urig, M. A., Simpson, G. F., Elliott, J. P., & Clewell, W. H. (1988). Twin-twin transfusion syndrome: The surgical removal of one twin as a treatment option. *Fetal Diagnosis and Therapy*, 3, 185–188.
- Ville, Y., Hecher, K., Gagnon, A., Sebire, N., Hyett, J., & Nicolaides, K. (1998). Endoscopic laser coagulation in the management of severe twin-to-twin transfusion syndrome. *British Journal of Obstetrics and Gynaecology*, 105, 446–453.
- Ville, Y., Hecher, K., Ogg, D., Warren, R., & Nicolaides, K. (1992). Successful outcome after Nd : YAG laser separation of chorioangiopagus-twins under sonoendoscopic control. *Ultrasound in Obstetrics and Gynecology*, 2, 429–431.
- Ville, Y., Hyett, J., Hecher, K., & Nicolaides, K. (1995). Preliminary experience with endoscopic laser surgery for severe twin-twin transfusion syndrome. *New England Journal of Medicine*, 332, 224–227.
- Wax, J. R., Blakemore, K. J., Blohm, P., & Callan, N. A. (1991). Stuck twin with cotwin nonimmune hydrops: Successful treatment by amniocentesis. *Fetal Diagnosis and Therapy*, 6, 126–131.
-