

Chronic Extradural Hematoma Presenting with Subgaleal Mass

GILBERT R.C. QUARTEY, YOUSSEF H. GABRIEL and STANLEY TCHANG

SUMMARY: *A case is reported of traumatic chronic extradural hematoma in a child who had previously undergone a craniotomy for a different lesion. Perforations made in the bone flap served as vents for extrusion of the hematoma fluid into the subgaleal space, thus decompressing the intracranial space. This resulted in a benign clinical course.*

RÉSUMÉ: *Nous rapportons un cas d'hématome extradural traumatique chronique chez un enfant qui avait subi préalablement une crâniotomie pour une lésion différente. Des perforations dans la calotte osseuse servirent de conduit pour permettre l'extrusion du liquide de l'hématome vers l'espace sousgaleen, permettant ainsi de décompresser l'espace intracrânien. Cette procédure devait permettre une évolution clinique bénigne.*

Extradural hematomas are known and dreaded as acute problems with a rapidly progressive clinical course. Several cases of chronic extradural hematomas have been reported. (Ask-enasy et al., 1962; Garza-Mercadeo and Campa, 1978; Iwakuma and Brunngraber, 1973; McLaurin and Ford, 1964). The interval from injury to operation has ranged from four days (Trowbridge et al., 1954) to six years (Grant, 1944). We are reporting a child whose extradural hematoma assumed a chronic course because of leakage of the hematoma fluid into the subgaleal space through perforations in the skull made previously during a craniotomy.

CASE REPORT

This four year-old boy was admitted to the University Hospital on May 28th, 1978 with one week's history of progressive scalp swelling in the left temporoparietal region. Head trauma was denied.

Three years previously he had presented with an enlarging head and investigations revealed a left parieto-occipital arachnoid cyst plus a chronic subdural hygroma. A large left frontoparietal craniotomy was performed with evacuation of the hygroma and excision of the outer membrane. The inner membrane was partially removed. The dura was closed in a watertight fashion and the free bone flap replaced after making small perforations in it through which the dura was hitched to the skull. Postoperatively his psychomotor development had been entirely satisfactory.

Examination revealed an intelligent left-handed boy with a large head, more prominent on the left side. A soft

tissue swelling was present in the left temporoparietal region occupying the central area of the previous scalp flap. There was no papilledema. He had a right spastic hemiparesis with hyperactive muscle stretch reflexes and an extensor plantar response.

Pneumoencephalography, carried out prior to sending the patient elsewhere for CT scanning, showed air filling the entire ventricular system. The midline structures were displaced to the right. A cystic lesion in the left frontal region communicated with the left lateral ventricle.

Under the clinical impression that the subgaleal space might contain cerebrospinal fluid, aspiration of the swollen area was carried out. Surprisingly, chronic hematoma fluid was obtained with resulting subsidence of the swelling. Within 18 hours, however, the mass gradually recurred.

The CT scan (Figure 1) showed lentiform lesions of low density in the left parietal region both extradurally and in the adjacent subgaleal space. There was also a chronic subdural hygroma. The ventricular system, containing residual air, was moderately dilated and displaced to the right. The left posterior lateral ventricle was deformed and compressed by an irregular area of low absorption representing residual arachnoid cyst.

On June 6th 1978 the previous left parietal craniotomy was reopened. A well-defined encapsulated chronic subgaleal hematoma, partly fluid and partly solid, was encountered and evacuated. A similar collection was found in the extradural space and also removed. The communication between the two spaces was through perforations in the bone flap (Figure 2). Upon opening the dura the subdural hygroma was encountered

From the Department of Clinical Neurological Sciences, University Hospital, Saskatoon, Saskatchewan.

Reprint requests to: Dr. Gilbert R.C. Quartey, Department of Neurosurgery, The Moncton Hospital, Moncton, New Brunswick, Canada E1C 6Z8.

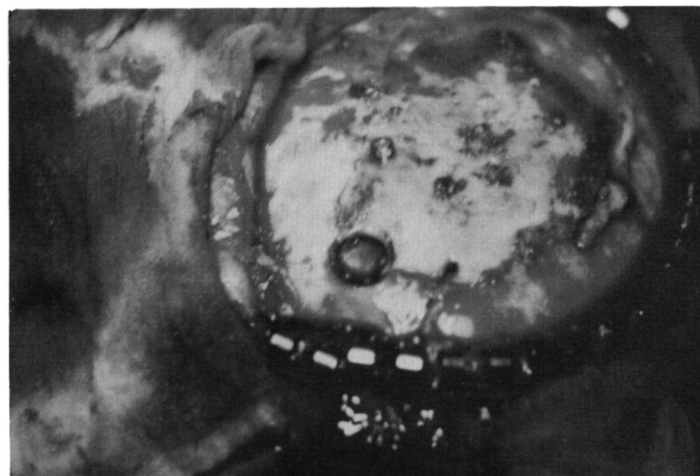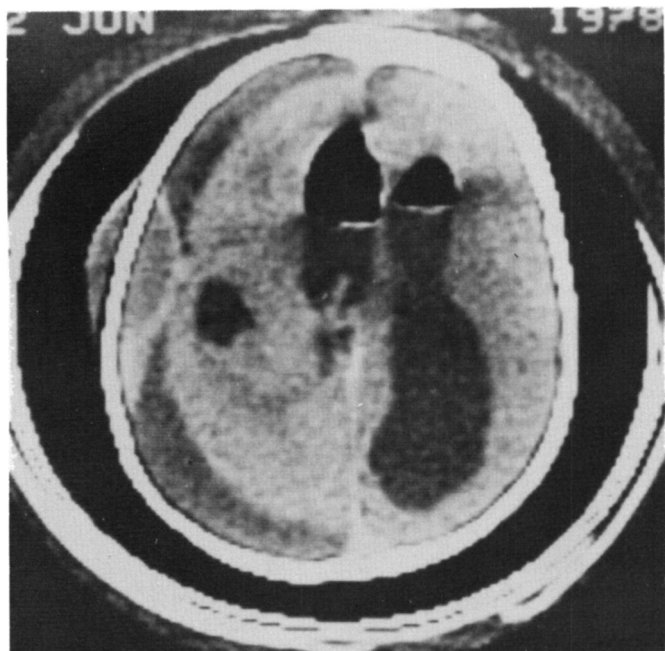


Figure 1 — Computerized tomography scan showing both extradural and subgaleal hematomas. A chronic subdural hygroma is demonstrated as well.

Figure 2 — Intra-operative pictures of bone flap showing perforations in the central area.

and evacuated. Excision of both outer and inner membranes was carried out. The left cerebral hemisphere was displaced about 2 cm from the inner table of the skull. A subduro-peritoneal shunt was established.

The boy's post-operative course was entirely satisfactory and when last reviewed in April 1979 he had no neurological deficit.

DISCUSSION

Mechanisms invoked to explain the chronic course of extradural hematomas include associated skull fracture with leakage of the hematoma fluid from the extradural space (Iwakuma and Brunngraber, 1973), frontally located hematomas (McLaurin and Ford, 1964; Jamieson and Yelland, 1968), venous source of bleeding (Askenasy et al., 1962; Jackson and Speakman, 1950; Trowbridge et al., 1954) and traumatic A-V fistulae of the meningeal vessels (Garza-Mercado and Campa, 1978; Iwakuma and Brunngraber, 1973).

Our patient illustrates another mechanism which attenuates the po-

tentially dangerous course of a hematoma in the extradural compartment. The perforations made in the bone flap during the previous craniotomy undoubtedly served as vents for extrusion of the fluid content of the hematoma into the subgaleal space. This resulted in spontaneous decompression of the intracranial space and a benign clinical course. Further, reaccumulation of the hematoma fluid in the subgaleal space after the aspiration lends support to this supposition. We believe that a significant head trauma was sustained, albeit denied, and caused hematoma formation almost certainly in both the subgaleal and extradural compartments. The presence of blood clots in the subgaleal space would tend to support this theory.

At surgery we were unable to determine precisely the source of bleeding. This is not surprising because in 13 of 21 cases of chronic extradural hematoma reported by Iwakuma and Brunngraber, (1973), no bleeding point was identified. However, the operative finding of encapsulated hematomas — solid clot plus brown fluid — is probably uncommon, as the

same authors encountered only two similar cases in their series of 21 patients.

REFERENCES

- ASKENASY, H.M., KOSARY, I.Z., BRAHAM, J. (1962). An insidiously developing form of extradural hematoma. *Neurochirurgia* 4: 206-211.
- GARZA-MERCADO, R., CAMPA, H. (1978). Extradural hematoma due to traumatic pseudoaneurysm of middle meningeal artery. *Surg Neurol* 9: 103-105.
- GRANT, W.T. (1944). Chronic extradural hematoma: Report of a case of hematoma in anterior cranial fossa. *Bull. Los Angeles Neurol Soc* 9: 156-162.
- IWAKUMA, T., BRUNNGRABER, C.V. (1973). Chronic extradural hematomas. A study of 21 cases. *J Neurosurg* 38: 488-493.
- JACKSON, I.T., SPEAKMAN, T.J. (1950). Chronic extradural hematoma. *J Neurosurg* 7: 444-447.
- JAMIESON, K.G., YELLAND, J.D.N. (1968). Extradural hematoma: Report of 167 cases. *J Neurosurg* 29: 13-23.
- McLAURIN, R.L., FORD, L.E. (1964). Extradural hematoma: statistical survey of forty-seven cases. *J Neurosurg* 21: 364-371.
- TROWBRIDGE, W.V., PORTER, R.W., FRENCH, J.D. (1954). Chronic extradural hematomas. *Arch Surg Chicago* 69: 824-830.