

Images

Giant Intrahepatic Biloma Following Blunt Hepatic Injury

Chien-Ze Peng, MBBS, MD*†; Chien-Ying Wang, MD*†

A previously healthy 26-year-old male was involved in a motorcycle crash resulting in an American Association for the Surgery of Trauma (AAST) grade IV liver

injury confirmed on CT scan (Figure 1A and B). The injury was treated with angioembolization. Following discharge, the patient complained of progressive

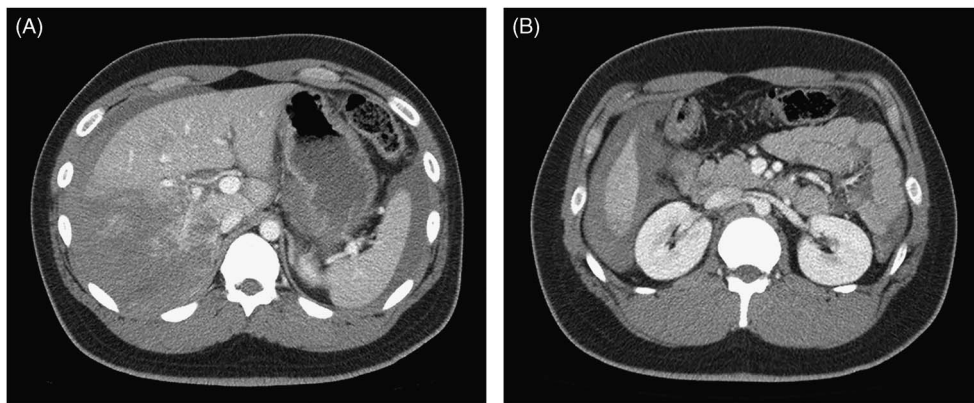


Figure 1A and 1B. Contrast-enhanced abdomen CT scan post-trauma showed lacerations in the right hepatic lobe with moderate amount hemoperitoneum.

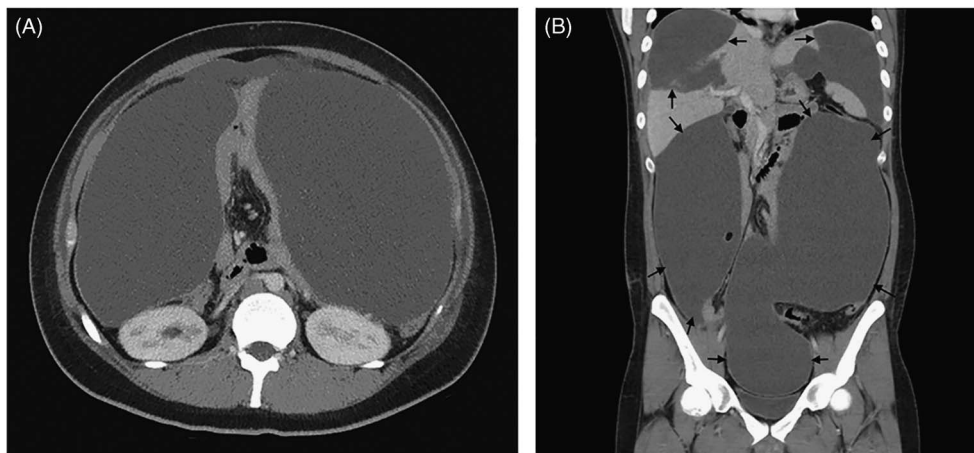


Figure 2A and 2B. Follow-up contrast-enhanced CT scan obtained three weeks later demonstrated an extensively large amount of intrahepatic low attenuation fluid collection with slightly thickening peritoneum causing mass effects to bowel loops.

From the *Emergency Department, Taipei- Veterans General Hospital, Taipei, Taiwan, R.O.C.; †Department of Emergency Medicine, National Yang-Ming University School of Medicine, Taipei, Taiwan, R.O.C.

Correspondence to: Chien-Ying Wang, Department of Emergency, National Yang-Ming University School of Medicine No. 201, Sec. 2, Shipai Rd., Beitou District, Taipei City, Taiwan 11217, R.O.C.; Email: czpeng@vghtpe.gov.tw

abdominal fullness and poor appetite. CT scan at three weeks demonstrated a large intrahepatic low attenuation fluid collection with slightly thickened peritoneum and some mass effect on bowel loops (Figure 2A and B).

Initial treatment consisted of percutaneous drainage. Because of lack of symptom resolution, the patient underwent exploratory laparotomy 45 days post-injury. This revealed a large bile collection with necrotic liver parenchyma, confirming the diagnosis of posttraumatic intrahepatic biloma.

Non-operative management (NOM) has become the standard of care for most hemodynamically stable blunt liver injured patients, with a reported success rate of more than 80%.¹ However, NOM of high-grade liver injuries was associated with significant morbidity. Biloma, biliary fistula, and bile peritonitis are potential complications of bile leakage, and have been seen in 6.4% of patients with blunt liver trauma.² Bilomas

occurring after blunt hepatic trauma usually remain asymptomatic and resolve spontaneously. Patients who require additional workup include those with increasing abdominal distension, worsening or persistent abdominal pain, feeding intolerance, or jaundice.

Competing Interests: None declared.

Keywords: biloma, blunt hepatic injury, non-operative management

REFERENCES

1. Richardson DJ, Franklin GA, Lukan JK, et al. Evolution in the management of hepatic trauma: a 25-year perspective. *Ann Surg* 2000;232(3):324-30.
2. Kozar RA, Moore FA, Cothren CC, et al. Risk factors for hepatic morbidity following nonoperative management: multicenter study. *Arch Surg* 2006;141(5):451-8; discussion 458-9.