

Female genital schistosomiasis (FGS) in Ogun State, Nigeria: a pilot survey on genital symptoms and clinical findings

U. F. EKPO^{1*}, O. M. ODEYEMI¹, S. O. SAM-WOBO¹, O. B. ONUNKWOR²,
H. O. MOGAJI^{1,3}, A. S. OLUWOLE¹, H. O. ABDUSSALAM⁴ and J. R. STOTHARD⁵

¹ Department of Pure and Applied Zoology, Federal University of Agriculture, Abeokuta, Nigeria

² Department of Biochemistry, Federal University of Agriculture, Nigeria

³ Department of Animal and Environmental Biology, Federal University Oye-Ekiti, Nigeria

⁴ Department of Obstetrics and Gynaecology, Federal Medical Centre, Abeokuta, Nigeria

⁵ Department of Parasitology, Liverpool School of Tropical Medicine, Pembroke Place, Liverpool L3 5QA, UK

(Received 16 December 2016; revised 19 June 2017; accepted 30 June 2017)

SUMMARY

The Nigerian national control programme (NCP) for schistosomiasis does not have a specific action plan for female genital schistosomiasis (FGS), mainly due to gaps in epidemiological and clinical surveillance. To address this, we conducted a pilot investigation for FGS in girls (>5 and ≤15 years) and adult women (≥16 years) in four rural communities near Abeokuta, Ogun State. Urine samples were collected from 317 participants [children ($n = 187$), adults ($n = 130$)] and examined for ova of *Schistosoma haematobium* by microscopy. A total of 149 participants (47.0%) had egg-patent urogenital schistosomiasis [children (64.7%), adults (21.6%)], reported blood in urine was common (44.5%) as well as sign-post symptoms of FGS. To verify FGS directly, 20 adult women each underwent a gynaecological investigation by colposcopy with observed lesions classified according to the WHO FGS pocket atlas. Fourteen (70.0%) women presented with FGS as grainy-sandy patches ($n = 10$), homogenous yellow sandy patches ($n = 6$), nabothian cysts and rubbery papules ($n = 1$). Our study confirms FGS in Ogun State and calls for further appraisals of this disease in other areas where urogenital schistosomiasis is endemic. The Nigerian NCP should be encouraged to develop an appropriate response to FGS not only to detect it, but also to prevent it.

Key words: *Schistosoma haematobium*, urogenital schistosomiasis, Female Genital Schistosomiasis, WHO FGS pocket atlas, colposcopy.

INTRODUCTION

Schistosomiasis is a disease of poverty, caused by infection with trematode parasites belonging to the genus *Schistosoma* (Colley *et al.* 2014). The disease is endemic in 75 countries, with over 200 million people affected and about 85% of these cases occurring in Africa (Steinmann *et al.* 2006; WHO, 2010). In sub-Saharan Africa (SSA) there are two forms of schistosomiasis, intestinal and urogenital, each associated with different schistosome species (Colley *et al.* 2014). The most pervasive form, urogenital schistosomiasis, is caused by *Schistosoma haematobium* and is predominant in Africa, Middle East and Corsica (WHO, 2016). The disease has a classic sign of haematuria (blood in urine), often with underlying fibrosis of the bladder and ureter, and in more advanced cases kidney damage (WHO, 2016). Across West Africa, schistosomiasis can be common in rural areas and in an attempt to control morbidity; there are several ongoing national control programmes (NCPs). These programmes are chiefly engaged in preventive chemotherapy

campaigns administering praziquantel *en masse* to targeted groups such as school-aged children (Lai *et al.* 2015; WHO, 2016).

Across SSA each form of schistosomiasis has a distribution, broadly tracking transmission foci where permissive freshwater intermediate snail hosts occur (Ekpo *et al.* 2013; Lai *et al.* 2015). In terms of urogenital schistosomiasis, Nigeria has one of the highest burdens in West Africa, with the disease endemic across all 36 States in the country. Around certain transmission foci in Ogun State, for example, local prevalence can very high ~90% (Akinwale *et al.* 2010) as water contact activities among the rural populace, albeit recreational and or domestic, are particularly common. These typically include: bathing, swimming, drinking, washing clothes or kitchen utensils and fetching of water, such that each activity serves as an often-daily pathway for acquiring infections (Ekpo *et al.* 2008, 2010, 2013; Sam-Wobo *et al.* 2009; Oladoyin *et al.* 2015).

With its predilection to colonize the lower pelvic venous system, especially the vesical plexus, eggs of *S. haematobium* are typically voided in urine and detected by urine microscopy (Stothard *et al.* 2014). Their exit causes micro-perforations in the

* Corresponding author. Federal University of Agriculture, Abeokuta, Nigeria. E-mail: ufekpo@hotmail.com

bladder wall with concomitant passage of venous blood, either in visible (macrohaematuria) or invisible (microhaematuria) amounts, the latter detectable by reagent strips (Stothard *et al.* 2014). Those eggs that fail to exit the body become trapped, trigger an immuno-inflammatory reaction and elicit 'classic' lower/upper urinary pathology as well as progressive damage in other internal organs (Colley *et al.* 2014; Dawaki *et al.* 2015). Whilst blood in urine is a cardinal sign of urogenital schistosomiasis; the condition may be so common in afflicted communities such that individuals accept and downplay its local clinical significance and largely ignore other sub-clinical morbidities. To better describe these disease states, advanced imagery, e.g. ultrasonography or semi-invasive methods, e.g. colposcopy is needed to visualize disease especially that of the lower genital tract (Kjetland *et al.* 2012; Holmen *et al.* 2014). Since such techniques are not available in primary health units, the manifestations of genital schistosomiasis go unnoticed whilst clinical symptoms may, for example, be attributed to sexually transmitted infections (STIs). Indeed, an incomplete surveillance and under-reporting of *S. haematobium* infection curtails the management of urogenital schistosomiasis in many rural parts of Africa (Stothard *et al.* 2014).

Upon migration within the tributaries of the internal iliac vein, adult *S. haematobium* eggs colonize other parts of the venous pelvic system causing damage to the reproductive organs and genitalia of both genders (Colley *et al.* 2014; Kjetland *et al.* 2014; Stecher *et al.* 2015; WHO, 2015). For example, schistosome eggs lodged in the uterine and vaginal venous plexus cause female genital schistosomiasis (FGS) which is a major detriment to women's health in SSA (HellingGiese *et al.* 1996a, b; Kjetland *et al.* 2008; Christinet *et al.* 2016). Although FGS was specifically recognized over 100 years ago, its pathology often mimics sexually transmitted diseases and is often incorrectly reported (Christinet *et al.* 2016). More recently, the importance of FGS in East, Central and Southern African (Poggensee *et al.* 1998, 2001; Poggensee and Feldmeier, 2001; Kjetland *et al.* 2008, 2012; Downs *et al.* 2011, 2013; Randrianasolo *et al.* 2015) has been much raised following several seminal studies leading to production and use of the FGS pocket colour atlas, endorsed by the WHO (Kjetland *et al.* 2014; Norseth *et al.* 2014; WHO, 2015). The FGS pocket atlas provides a useful reference guide to describe the disease upon colposcopy, intending to empower disease surveillance systems to observe and report this condition.

In Nigeria, the geographical distribution of *S. haematobium* is extensive, and the NCP is attempting to establish large-scale control activities in several disease-endemic states (Ekpo *et al.* 2013). However, there are several states where preventive

chemotherapy has not yet been rolled out, and more generally there are no specific actions on FGS in any areas. Here, we report on the findings of a pilot survey for FGS undertaken in Ogun State where *S. haematobium* is endemic, and no formal control programme currently exists.

MATERIALS AND METHODS

Study area and subjects

The epidemiological and clinical survey was undertaken in four villages of Abule-Titun, Apojola, Ibaro and Imala-Odo, near Abeokuta, Ogun State. All villages are located on the immediate shoreline of Oyan River dam (7°15'30" N, 3°15'20" E), and were known to be highly endemic since 1991 till date (Ofoezie *et al.* 1991; Mafiana *et al.* 2003; Akinwale *et al.* 2010; Ekpo *et al.* 2012). All resident young girls (>5–16 years old) and women of child bearing age (>16–49 years old) were invited to participate in the study. The communities (average size of 200 inhabitants) are predominantly fishing settlements established soon after the construction of the Oyan River dam (Ofoezie *et al.* 1991). Locally there is an annual school-based treatment campaign in school children, but infections in pre-school children and non-enrolled school-aged children are not treated. Similarly, the Ogun State does not provide access to preventive treatment for adults although praziquantel can be purchased in nearby private pharmacies at a cost of 1 USD per tablet.

Ethical approval and considerations

Ethical approval was granted by the ethical review board of State Hospital Ijaye, and Ogun State Ministry of Health, Abeokuta. Community sensitization and mobilization was initially undertaken through the primary health care coordinator and local headman/community leader in each village. After explaining the objectives of the study informed written consent was obtained from the child's guardian and adult participant. All participant consenting to the study procedures were provided with praziquantel treatment (40 mg kg⁻¹) in accordance with their height, using dosing poles.

Participant interviews and questionnaires

Participant interview was conducted on site by the field team. A questionnaire was used to obtain information on socio-demographic characteristics, and each participant was asked to describe any urogenital signs and symptoms they were experiencing currently or recently. In an attempt to standardize symptomologies a vaginal discharge colour chart (Fig. 1) was used to clarify discussions

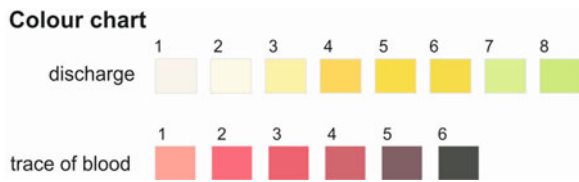

Fig. 1. Standardized symptomologies using a vaginal discharge colour chart (Hegertun *et al.* 2013) for visual comparisons.

(Hegertun *et al.* 2013). The colour chart exemplifies presence of blood or vaginal discharge. Environmental risk factors such as participants' day-to-day water contact activities putatively associated with urinary schistosomiasis and FGS were ascertained through more in-depth interviews. All discussions were made in local languages and simplified to the best understanding of the young female children (5–15 years).

Diagnosis of urogenital schistosomiasis

A 10 mL mid-stream urine sample was collected from each participant during late morning or early afternoon. Urines were preserved with 10% formaldehyde and transported to the laboratory chilled on ice-packs for light microscopy. Samples were centrifuged at 1500 rpm for 10 min in a benchtop centrifuge, and sediments were examined for ova of *S. haematobium* at $\times 100$ magnification. Sample processing and examination, as well as clinical investigations and colposcopy, were undertaken by a female gynaecologist in the local community health facility.

Colposcopy and clinical examination for FGS

Twenty adult female participants out of the 317 participants consented to gynaecological examination by a female gynaecologist. Examination commenced with vaginal lavage with a solution of 3% sodium chloride then followed by photo-colposcopy. The

cervico-vaginal surfaces were inspected following guidelines in the outlined in the WHO FGS pocket atlas, specifically noting five clinically visible manifestations: contact bleeding, pre-contact bleeding, yellow sandy patches, grainy sandy patches and abnormal blood vessels (WHO, 2015). FGS was defined as having grainy sandy patches or homogenous yellow sandy patches. Tissue biopsy of the cervico-vaginal surface was not performed.

Data tabulations and statistical analysis

Raw data were entered into Excel database and then analysed using SPSS IBM 20.0 version, Armonk, NY, IBM Corp. Data were first subjected to descriptive statistics, including frequencies and cross-tabulations, followed by Pearson Chi-square analysis to test for variables that were significantly associated with urogenital schistosomiasis.

RESULTS

Demographic status of participants

A total of 317 participants, 187 girls and 130 adult women were recruited into the study with 64 (20.2%) from Ibaro; 131 (41.3%) from Imala-Odo; 69 (21.8%) from Abule-Titun and 53 (16.7%) from Apojola communities. Amongst the adults, almost all were married, and only one person was separated. 65.6% (208/317) of the participants had primary education (Table 1).

Urogenital schistosomiasis and water contact behaviours

The overall prevalence of urogenital schistosomiasis was 47.0% (149/317) with an overall geometric mean egg intensity (GMI) of 0.77 eggs per 10 mL (Table 2). There was a significant difference ($P < 0.05$) between the prevalence and intensity of

Table 1. Demographic characteristics of participants

Variables		Oyan river villages				Total N = 317 (%)
		Ibaro n = 64 (%)	Imala-Odo n = 131 (%)	Abule-titun n = 69 (%)	Apojola n = 53 (%)	
Age group	5–15	36 (56.2)	88 (67.2)	33 (47.9)	30 (56.6)	187 (59.0)
	16–25	11 (17.2)	22 (16.8)	17 (24.6)	12 (22.6)	62 (19.6)
	26–49	17 (26.6)	21 (16.0)	19 (27.5)	11 (20.8)	68 (21.4)
Education status	Informal	10 (15.6)	23 (17.6)	10 (14.5)	9 (17.0)	52 (16.5)
	Primary	44 (68.7)	88 (67.2)	43 (62.3)	34 (64.2)	208 (65.6)
	Secondary	10 (15.6)	19 (14.5)	16 (23.2)	10 (18.8)	55 (17.5)
	Tertiary	0 (0.0)	1 (0.7)	0 (0.0)	0 (0.0)	1 (0.3)
Marital status	Not married	45 (70.3)	100 (76.3)	34 (49.3)	39 (73.6)	218 (68.8)
	Married	18 (28.1)	31 (23.7)	35 (50.7)	14 (26.4)	98 (30.9)
	Separated	1 (1.6)	0 (0.0)	0 (0.0)	0 (0.0)	1 (0.3)

Table 2. Prevalence and Geometric Mean Intensities of urinary schistosomiasis across demographic characteristics of participants

	Number examined	Number infected	GMI (eggs per 10 mL of urine) + s.e.
Prevalence of urinary schistosomiasis	317	149 (47.0)	0.77 ± 0.43
Study villages			
Ibaro	64	29 (45.3)	0.63 ± 0.92 ^b
Imala-Odo	131	77 (58.8)	0.73 ± 0.62 ^b
Abule-titun	69	11 (15.9)	0.23 ± 0.65 ^a
Apojola	53	32 (60.4)	1.07 ± 0.12
Total	317	149 (47.0)	0.78 ± 0.43
<i>P</i> value		<0.05	
Age group (years)			
5–15	187	121 (64.7)	0.95 ± 0.56 ^b
16–25	62	18 (29.0)	0.42 ± 0.85 ^a
26–49	68	10 (14.7)	0.19 ± 0.58 ^a
Total	317	149 (47.0)	0.78 ± 0.43
<i>P</i> value		<0.05	
Marital status			
Single	218	134 (61.5)	0.90 ± 0.05 ^a
Married	98	15 (15.3)	0.21 ± 0.05 ^b
Separated	1	0 (0.0)	–
Total	317	149 (47.0)	0.78 ± 0.43
<i>P</i> value		<0.001	

GMI, Geometric Mean Intensity (mean values with the same superscript are not significantly different at $P < 0.05$).

Table 3. Self-reported symptoms and association with egg-patent urinary schistosomiasis

	Number of respondents (%)				<i>P</i> -value
	5–15 years (<i>n</i> = 187)	16–25 years (<i>n</i> = 62)	26–49 years (<i>n</i> = 68)	Total (<i>N</i> = 317)	
Symptoms					
Haematuria (blood in urine)	112 (79.4)	20 (14.2)	9 (6.4)	141 (44.5)	<0.001
Vaginal itching	79 (56.8)	28 (20.1)	32 (23.0)	139 (43.8)	0.922
Burning sensation	69 (58.9)	20 (17.1)	28 (23.9)	117 (36.9)	0.480
Vagina swelling/lump	22 (45.8)	13 (27.1)	13 (27.1)	48 (15.1)	0.235
Vaginal discharge ^a	27 (31.0) ^b	26 (29.9)	34 (39.1)	87 (27.4)	<0.001
Stress incontinence	55 (52.9)	24 (23.1)	25 (24.0)	104 (32.8)	0.109
Urge incontinence	68 (55.7)	28 (22.9)	26 (21.3)	122 (38.4)	0.784
Dysuria	96 (60.8)	30 (18.9)	32 (20.3)	158 (49.8)	0.972

^a The vaginal discharge was classified against colour reference chart FGS with associated severity risk grade (Fig. 1).

^b 11 yellow discharges (graded 8+), 9 brown discharges (graded 5+), 5 red discharges (graded 2+), 1 black discharge (graded 8+) and 1 butter discharge (graded 4+).

Table 4. Occurrence and clinical presentation of FGS within the 20 women examined

	Number of participants (%)
FGS pathology	
Sandy patches on homogenous Yellow area	6 (30.0)
Grainy sandy patches	10 (50.0)
Nabothian cysts	1 (5.0)
Cervical polyps only	1 (5.0)
Rubbery papules	1 (5.0) ^a
Abnormal blood vessels	3 (15.0)
Suspected cancerous growth	1 (5.0)

^a This is the first time this condition has been reported outside of Madagascar (Randrianasolo *et al.* 2015).

urogenital schistosomiasis by age categories of participants. Prevalence and intensity was significantly ($P < 0.05$) higher among children aged 5–15 years (64.7%) with GMI of 0.95 ± 0.56 eggs per 10 mL of urine than young adult women aged 16–25 years 29.0% with GMI of 0.42 ± 0.86 eggs per 10 mL of urine and adult women aged 26–49 years 14.7% with GMI of 0.19 ± 0.59 eggs per 10 mL. By village, significant differences ($P < 0.05$) were found between mean intensities recorded across the four communities surveyed. In terms of water contact, 294 (92.7%) fetched water every day from the dam, 166 (52.4%) engaged in fishing activities, 296 (93.4%) washed clothes at the dam, while 306 (96.5%) bathed or swam in the dam.

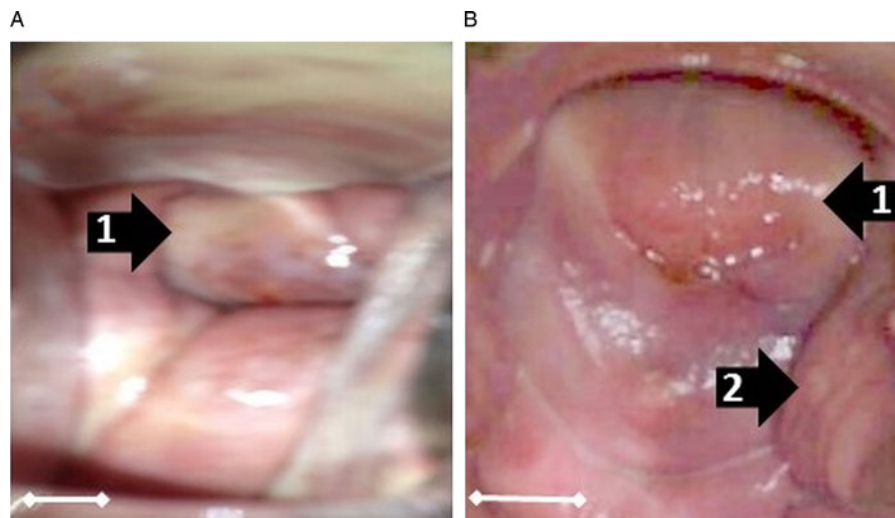


Fig. 2. Vaginal or cervical anomalies seen in FGS cases. Images of cervix taken using colposcopy. (A) Grainy sandy patches (1) and homogenous yellow sandy patches around the cervical wall; (B) Sandy patches: (1) and rubbery papules (2) and homogenous yellow sandy patches around the cervical wall (Scale bar indicates 1 cm).

Self-reported symptoms and colposcopy

Female participants reported symptoms such as blood in urine, itching of the vaginal, burning sensation in the genital area, swelling/lump, stress incontinence, urge incontinence and dysuria. Only two symptoms (haematuria and vaginal discharge) showed significance across the age categories. Female participants aged 5–15 years had the highest morbidity prevalence for haematuria, while those aged 26–49 years had the highest morbidity prevalence for vaginal discharge (Table 3). Of the 87 (27.4%) respondents that recalled having virginal discharges, only 27 (31.0%) could recall the colour of the vaginal discharge they had experienced in the past or were currently experiencing with the majority 11 (40.7%) recalling a yellow vaginal colour discharge. Other colours forms of discharges were in form of brown, 9 (33.3%); red, 5 (18.5%), black, 1 (3.7%) and butter, 1 (3.7%) colours, respectively.

Twenty women out of the 317 study participants (6.3%) consented to gynaecological and a photo-colposcopic examinations (Table 4). Upon examination

14 (70.0%) had vaginal or cervical anomalies (Fig. 2) that could be classified according to the WHO FGS pocket atlas (Table 4). The symptomatic profile of females presenting FGS pathology includes dysuria (57.1%), vaginal itching (42.6%), vaginal swelling (28.6%) and burning sensation (28.6%) is shown in (Table 5), while the profile and FGS pathology among the 20 women who consented to gynaecological examination is presented in Table 6.

DISCUSSION

Among the females, with urogenital schistosomiasis, one third reported to have vaginal discharge and just under half of the study participants had *S. haematobium* eggs visible in the urine indicative of active urogenital schistosomiasis. As only a single urine sample was taken the actual prevalence of active as well as past infection with urogenital schistosomiasis is likely higher, for in the light of daily water contact activities undertaken in these villages, such as swimming, bathing, washing clothes, fishing, etc., the risk here is universal. Typical of the age-prevalence relationship for urinary schistosomiasis, egg-patent prevalence was higher in the 5–15-year-old category. Nonetheless, some of the older girls and adult women were excreting eggs in urine. Whilst there have been several reports describing prevalence and intensity of urogenital schistosomiasis along this shoreline, and in Ogun State in general (Mafiana *et al.* 2003; Ekpo *et al.* 2008, 2010; Akinwale *et al.* 2010), there has been no prior attempt to document the occurrence of FGS here or elsewhere in Nigeria.

Of the women that volunteered for genital examination, we found that more than half had clinical manifestations of FGS. It is remarkable that such a locally pervasive disease, which is of obvious

Table 5. Reported symptoms in women presenting with FGS

	Female genital schistosomiasis (FGS)	
	Positive cases	Symptomatic participants (%)
Abnormal vaginal discharge	14	4 (28.6)
Vagina itching	14	6 (42.9)
Dysuria	14	8 (57.1)
Vagina swelling	14	4 (28.6)
Burning sensation	14	4 (28.6)

Table 6. Profile and FGS pathology among the 20 women consenting to gynaecological examination

s/n	Status of urinary schistosomiasis among the screened women	GMI or eggs per 1 mL of urine	Age	Marital status of the screened women	Probable symptoms associated with FGS						FGS pathology						FGS status among screened women	
					Vaginal discharge colour, if any	Vaginal itching	Dysuria	Urge incontinence	Vaginal swelling	Burning sensation	Grainy sandy patches	Sandy patches on homogeneous yellow area	Rubbery papules	Nabothian cyst	Cervical polyps	Vascular changes		Suspected cancerous growth
1	Positive	0.8	30	Married	Red	Yes	Yes	Yes	Yes	Yes	Yes	No	Yes	Yes	Yes	Yes	Yes	Positive
2	Positive	0.9	21	Married	White	No	Yes	Yes	No	No	Yes	No	No	No	No	No	No	Positive
3	Positive	1.4	25	Single	Yellow	Yes	Yes	Yes	Yes	Yes	Yes	No	No	No	No	No	No	Positive
4	Positive	1.5	30	Married	No discharge	Yes	Yes	Yes	No	Yes	Yes	No	No	No	No	No	No	Positive
5	Positive	1.5	35	Married	Brown	No	No	No	No	No	Yes	No	No	No	No	No	No	Positive
6	Positive	0.9	40	Married	No discharge	Yes	Yes	Yes	Yes	Yes	Yes	No	No	No	No	No	No	Positive
7	Positive	1.5	20	Married	No discharge	No	Yes	Yes	No	No	No	Yes	No	No	No	No	Yes	Positive
8	Positive	1.0	40	Single	No discharge	Yes	Yes	Yes	Yes	No	No	Yes	No	No	No	No	No	Positive
9	Positive	1.8	20	Married	White	No	No	No	No	No	Yes	No	No	No	No	No	No	Positive
10	Positive	1.5	45	Married	No discharge	No	No	No	No	No	Yes	No	No	No	No	No	No	Positive
11	Positive	1.8	35	Single	No discharge	No	No	No	No	No	No	Yes	No	No	No	No	No	Positive
12	Positive	1.2	35	Married	No discharge	No	No	No	No	No	No	Yes	No	No	No	No	No	Positive
13	Positive	1.1	23	Married	Yellow	Yes	Yes	No	No	No	Yes	Yes	No	No	No	No	Yes	Positive
14	Positive	1.4	35	Married	No discharge	No	No	No	No	No	Yes	Yes	No	No	No	No	No	Positive
15	Positive	1.9	5	Married	White	Yes	Yes	Yes	Yes	No	No	No	No	No	No	No	No	Negative
16	Positive	1.3	11	Single	White	Yes	Yes	No	Yes	No	No	No	No	No	No	No	No	Negative
17	Positive	1.9	21	Married	No discharge	No	No	No	No	No	No	No	No	No	No	No	No	Negative
18	Positive	1.7	28	Married	No discharge	No	Yes	Yes	No	No	No	No	No	No	No	No	No	Negative
19	Positive	1.9	24	Married	No discharge	No	No	No reply	No	No reply	No	No	No	No	No	No	No	Negative
20	Positive	1.4	27	Married	No discharge	No	No	No reply	No	No reply	No	No	No	No	No	No	No	Negative

detriment to the health of women has not attracted more attention, although like elsewhere in Nigeria many perhaps suffer in silence (Dawaki *et al.* 2015). Surveillance for FGS has been totally overlooked, whilst the disease has been firmly engrained in these communities for decades, first formally reported in 1991 (Ofozie *et al.* 1991). More broadly, clinical surveillance of FGS in West Africa has not been undertaken largely due to lack of awareness and inexperience of health personnel at all cadres (Christinet *et al.* 2016; Holmen *et al.* 2016), inadequate resources for its detection within the primary care setting (WHO, 2015), as well as competing interests and priorities within NCPs that tackle more obvious issues associated with administration of preventive chemotherapy. The latter is an unfortunate polarity which on the one hand monitors and treats urinary signs and symptoms of schistosomiasis yet on the other totally neglects genital tract involvement.

To address this and building on seminal work in central and southern Africa, the production of the WHO FGS pocket atlas has attempted to spearhead concerted action against this FGS (Christinet *et al.* 2016). This is by encouraging both epidemiological and clinical studies; from an epidemiological perspective, introducing the use of simple symptomology questionnaires is eminently feasible in resource constrained settings and has shown to be informative (Kjetland *et al.* 2008; Holmen *et al.* 2014). Where further clinical resources are available, the colour plate illustrations of pathognomonic lesions help to identify and classify vagino-cervical pathologies (Norseth *et al.* 2014). Table 3 shows that a variety of symptoms were reported, the most significant of which appeared to be abnormal vaginal discharge. This was further categorized by making use of a simple visual colour chart for comparison (Hegertun *et al.* 2013). Similarly, Table 4 shows by colposcopy, a total of 70.0% of women had patent genital tract disease, which could be graded into typical FGS lesions, e.g. sandy patches and homogenous yellow areas. This level, although high is not surprising in light of FGS, reported in other parts of Africa (Kjetland *et al.* 2012, 2014). Two weaknesses of our study, however, was that firstly, we made no attempt to investigate other sexually transmitted infections that may cause similar symptoms as that of FGS and secondly, only women with active urogenital schistosomiasis consented and underwent colposcopic procedures. Thus, there probably remains an unknown proportion of women who may have FGS without active *Schistosoma* egg-excretion in the urine. This should be investigated in greater detail as it is well known that FGS is not always predicted by urine-egg patency (Poggensee *et al.* 1998; Holmen *et al.* 2014).

Conducting colposcopy is certainly a critical step in detection and classification of clinical FGS as

presented by visual lesions on the surfaces of the vagina and cervix. Where colposcopy is not possible, there should be alternative attempts to detect and confirm FGS (Randrianasolo *et al.* 2015), especially by application of more sensitive diagnostic methods that detect schistosome eggs or biomarker thereof before more serious lesion develop in the genitalia (Pillay *et al.* 2014, 2016). For example, if biopsy material or vaginal lavage fluid was more readily available than both histology and molecular DNA approaches could be used (Randrianasolo *et al.* 2015). The latter would only be possible if the eggs are viable, whereas calcified eggs would not excrete DNA. With promotion of the Sustainable Development Goals, there will be greater attention placed on women's well-being, which in part will focus upon reducing cervical cancers and increased screening for human papilloma virus (HPV) (Coleman *et al.* 2016). It is evident that where urinary schistosomiasis is co-endemic the health system should integrate detection of FGS within such wider surveillance. By that token, praziquantel treatment should be made available to all women who are shown to have urogenital schistosomiasis or are at-risk of acquiring it in childhood (Bustinduy *et al.* 2016). We, therefore, encourage the Nigerian NCP to expand future access of praziquantel to all women at-risk and orchestrate an appropriate response to the challenge that FGS poses not only to detect it, but also prevent it.

Conclusion

Our pilot study has confirmed the occurrence of FGS in Ogun State, Nigeria and highlights that a substantive proportion of women with urogenital schistosomiasis have underlying gynaecological disease that is currently overlooked. We encourage the Nigerian NCP to develop a specific action plan against FGS and orchestrate an appropriate response not only to detect it, but also prevent it. Otherwise, millions of African women will continue to suffer unduly.

ACKNOWLEDGEMENTS

We are grateful to the study participants who generously gave their time to be involved in this study. We thank Dr Eyrun Kjetland for advice on colposcopy and providing FGS standardized vaginal discharge colour chart. Professor J. R. Stothard is Director of COUNTDOWN, an implementation research consortium that receives support from DFID, UK to support scale-up of interventions against neglected tropical diseases in Nigeria.

FINANCIAL SUPPORT

This research received no specific grant from any funding agency, commercial or not-for-profit sectors.

CONFLICT OF INTEREST

None.

ETHICAL STANDARDS

The authors assert that all procedures contributing to this work comply with the ethical standards of the relevant national and institutional committees on human experimentation and with the Helsinki Declaration of 1975, as revised in 2008

REFERENCES

- Akinwale, O. P., Ajayi, M. B., Akande, D. O., Gyang, P. V., Adeleke, M. A., AK Adeneye, A. K., MO Adebayo, M. O. and Dike, A. A. (2010). Urinary schistosomiasis around Oyan Reservoir, Nigeria: twenty years after the first outbreak Iranian. *Journal of Public Health* **39**, 92–95.
- Bustinduy, A. L., Friedman, J. F., Kjetland, E. F., Ezeamama, A. E., Kabatereine, N. B., Stothard, J. R. and King, C. H. (2016). Expanding praziquantel (PZQ) access beyond mass drug administration programs: paving a way forward for a pediatric PZQ formulation for schistosomiasis. *PLoS Neglected Tropical Diseases* **10**. doi: 10.1371/journal.pntd.0004946.
- Christinet, V., Lazdins-Helds, J. K., Stothard, J. R. and Reinhard-Rupp, J. (2016). Female genital schistosomiasis (FGS): from case reports to a call for concerted action against this neglected gynaecological disease. *International Journal for Parasitology* **46**, 395–404.
- Coleman, J. S., Cespedes, M. S., Cu-Uvin, S., Kosgei, R. J., Maloba, M., Anderson, J., Wilkin, T., Jaquet, A., Bohlius, J., Anastos, K. and Wooll-Kaloustian, K. (2016). An insight into cervical cancer screening and treatment capacity in sub Saharan Africa. *Journal of Lower Genital Tract Disease* **20**, 31–37.
- Colley, D. G., Bustinduy, A. L., Secor, E. and King, C. H. (2014). Human schistosomiasis. *Lancet* **383**, 2253–2264.
- Dawaki, S., Al-Mekhlafi, H. M., Ithoi, I., Ibrahim, J., Abdulsalam, A. M., Ahmed, A., Sady, H., Nasr, N. A. and Atroosh, W. M. (2015). The menace of schistosomiasis in Nigeria: knowledge, attitude, and practices regarding schistosomiasis among rural communities in Kano State. *PLoS ONE* **10**. doi: 10.1371/journal.pone.0143667.
- Downs, J. A., Mguta, C., Kaatano, G. M., Mitchell, K. B., Bang, H., Simplice, H., Kalluvya, S. E., Changalucha, J. M., Johnson, W. D. and Fitzgerald, D. W. (2011). Urogenital schistosomiasis in women of reproductive age in Tanzania's Lake Victoria Region. *American Journal of Tropical Medicine and Hygiene* **84**, 364–369.
- Downs, J. A., Kabangila, R., Verweij, J. J., Jaka, H., Peck, R. N., Kalluvya, S. E., Changalucha, J. M., Johnson, W. D., van Lieshout, L. and Fitzgerald, D. W. (2013). Detectable urogenital schistosoma DNA and cervical abnormalities 6 months after single-dose praziquantel in women with *Schistosoma haematobium* infection. *Tropical Medicine and International Health* **18**, 1090–1096.
- Ekpo, U. F., Mafiana, C. F., Adeofun, C. O., Solarin, A. R. T. and Idowu, A. B. (2008). Geographical information system and predictive risk maps of urinary schistosomiasis in Ogun State, Nigeria. *BMC Infectious Diseases* **8**, 74. doi: 10.1186/1471-2334-8-74.
- Ekpo, U. F., Laja-Deile, A., Oluwole, A. S., Sam-Wobo, S. O. and Mafiana, C. F. (2010). Urinary schistosomiasis among preschool children in a rural community near Abeokuta, Nigeria. *Parasites and Vectors* **3**, 58. doi: 10.1186/1756-3305-3-58.
- Ekpo, U. F., Fafunwa, T. S., Oluwole, A. S., Abe, E. M. and Mafiana, C. F. (2012). Prevalence and factors associated with urinary schistosomiasis among infants and preschool-aged children in settlements around Oyan reservoir in Ogun State, Nigeria. *Journal of Natural Sciences, Engineering, and Technology* **11**, 82–92.
- Ekpo, U. F., Huerlimann, E., Schur, N., Oluwole, A. S., Abe, E. M., Mafe, M. A., Nebe, O. J., Isiyaku, S., Olamiju, F., Kadiri, M., Poopola, T. O. S., Braide, E. I., Saka, Y., Mafiana, C. F., Kristensen, T. K., Utzinger, J. and Vounatsou, P. (2013). Mapping and prediction of schistosomiasis in Nigeria using compiled survey data and Bayesian geospatial modelling. *Geospatial Health* **7**, 355–366.
- Hegertun, I. E. A., Sulheim Gundersen, K. M., Kleppa, E., Zulu, S. G., Gundersen, S. G., Taylor, M., Kvalsvig, J. D. and Kjetland, E. F. (2013). *S. haematobium* as a common cause of genital morbidity in girls: a cross-sectional study of children in South Africa. *PLoS Neglected Tropical Diseases* **7**, e2104.
- HellingGiese, G., Kjetland, E. F., Gundersen, S. G., Poggensee, G., Richter, J., Krantz, I. and Feldmeier, H. (1996a). Schistosomiasis in women: manifestations in the upper reproductive tract. *Acta Tropica* **62**, 225–238.
- HellingGiese, G., Sjaastad, A., Poggensee, G., Kjetland, E. F., Richter, J., Chitsulo, L., Kumwenda, N., Racz, P., Roald, B., Gundersen, S. G., Krantz, I. and Feldmeier, H. (1996b). Female genital schistosomiasis (FGS): relationship between gynecological and histopathological findings. *Acta Tropica* **62**, 257–267.
- Holmen, S., Galappaththi-Arachchige, H. N., Kleppa, E., Pillay, P., Naicker, T., Taylor, M., Onsrud, M., Kjetland, E. F. and Albrechtsen, F. (2016). Characteristics of blood vessels in female genital schistosomiasis: paving the way for objective diagnostics at the point of care. *PLoS Neglected Tropical Diseases* **10**, e0004628.
- Holmen, S. D., Onsrud, M., Vennervald, B. J., Albrechtsen, F., Taylor, M., Moodley, J., van Lieshout, L., Pillay, P., Lillebo, K., Kleppa, E. and Kjetland, E. F. (2014). Diagnosing female genital schistosomiasis. *International Journal of Infectious Diseases* **21**, 169.
- Kjetland, E. F., Kurewa, E. N., Ndhlovu, P. D., Midzi, N., Gwanzura, L., Mason, P. R., Gomo, E., Sandvik, L., Mduluzza, T., Friis, H. and Gundersen, S. G. (2008). Female genital schistosomiasis – a differential diagnosis to sexually transmitted diseases: genital itch and vaginal discharge as indicators of genital *Schistosoma haematobium* morbidity in a cross-sectional study in endemic rural Zimbabwe. *Tropical Medicine and International Health* **13**, 1509–1517.
- Kjetland, E. F., Leutscher, P. D. C. and Ndhlovu, P. D. (2012). A review of female genital schistosomiasis. *Trends in Parasitology* **28**, 58–65.
- Kjetland, E. F., Norseth, H. M., Taylor, M., Lillebo, K., Kleppa, E., Holmen, S. D., Andebirhan, A., Yohannes, T. H., Gundersen, S. G., Vennervald, B. J., Bagratee, J., Onsrud, M. and Leutscher, P. D. C. (2014). Classification of the lesions observed in female genital schistosomiasis. *International Journal of Gynecology and Obstetrics* **127**, 227–228.
- Lai, Y. S., Biedermann, P., Ekpo, U. F., Garba, A., Mathieu, E., Midzi, N., Mwinzi, P., N'Goran, E. K., Raso, G., Assare, R. N. K., Sacko, M., Schur, N., Talla, I., Tchuente, L. A. T., Toure, S., Winkler, M. S., Utzinger, J. and Vounatsou, P. (2015). Spatial distribution of schistosomiasis and treatment needs in sub-Saharan Africa: a systematic review and geostatistical analysis. *Lancet Infectious Diseases* **15**, 927–940.
- Mafiana, C. F., Ekpo, U. F. and Ojo, D. A. (2003). Urinary schistosomiasis in preschool children in settlements around Oyan Reservoir in Ogun State, Nigeria: implications for control. *Tropical Medicine and International Health* **8**, 78–82.
- Norseth, H. M., Ndhlovu, P. D., Kleppa, E., Randrianasolo, B. S., Jourdan, P. M., Roald, B., Holmen, S. D., Gundersen, S. G., Bagratee, J., Onsrud, M. and Kjetland, E. F. (2014). The colposcopic atlas of schistosomiasis in the lower female genital tract based on studies in Malawi, Zimbabwe, Madagascar and South Africa. *PLoS Neglected Tropical Diseases* **8**. doi: 10.1371/journal.pntd.0003229.
- Ofoezie, I. E., Imevbore, A. A. A., Balogun, M. O., Ogunkoya, O. O. and Asalu, S. O. (1991). A study of an outbreak of schistosomiasis in two resettlement villages near Abeokuta, Ogun State, Nigeria. *Journal of Helminthology* **65**, 95–102.
- Oladoyin, V., Akindele, A. and Uchendu, O. (2015). Schistosomiasis: a neglected disease in a neglected group in Nigeria. *International Journal of Epidemiology* **44**, 280–281.
- Pillay, P., Taylor, M., Zulu, S., Gundersen, S. G., Kleppa, E., Lillebo, K., Kjetland, E. F., Brienen, E. and van Lieshout, L. (2014). *Schistosoma* PCR among high school girls in South Africa as a complementary diagnostic tool for Female Genital Schistosomiasis (FGS). *International Journal of Infectious Diseases* **21**, 171.
- Pillay, P., van Lieshout, L., Taylor, M., Sebitloane, M., Zulu, S. G., Kleppa, E., Roald, B. and Kjetland, E. F. (2016). Cervical cytology as a diagnostic tool for female genital schistosomiasis: correlation to cervical atypia and *Schistosoma* polymerase chain reaction. *Cytojournal* **13**, 10. <http://doi.org/10.4103/1742-6413.180784>.
- Poggensee, G. and Feldmeier, H. (2001). Female genital schistosomiasis: facts and hypotheses. *Acta Tropica* **79**, 193–210.
- Poggensee, G., Kiwelu, I., Saria, M., Richter, J., Krantz, I. and Feldmeier, H. (1998). Schistosomiasis of the lower reproductive tract without egg excretion in urine. *American Journal of Tropical Medicine and Hygiene* **59**, 782–783.
- Poggensee, G., Sahebali, S., Van Marck, E., Swai, B., Krantz, I. and Feldmeier, H. (2001). Diagnosis of genital cervical schistosomiasis:

comparison of cytological, histopathological and parasitological examination. *American Journal of Tropical Medicine and Hygiene* **65**, 233–236.

Randrianasolo, B. S., Jourdan, P. M., Ravoniarimbinina, P., Ramarokoto, C. E., Rakotomanana, F., Ravaoalimalala, V. E., Gundersen, S. G., Feldmeier, H., Vennervald, B. J., van Lieshout, L., Roald, B., Leutscher, P. and Kjetland, E. F. (2015). Gynecological manifestations, histopathological findings, and *Schistosoma*-specific polymerase chain reaction results among women with *Schistosoma haematobium* infection: a cross-sectional study in Madagascar. *Journal of Infectious Diseases* **212**, 275–284.

Sam-Wobo, S. O., Ekpo, U. F., Ameh, I. G. and Osileye, O. T. (2009). Continued high endemicity of urinary schistosomiasis in Ogun State, Nigeria. *Nigerian Journal of Parasitology* **30**, 48–52.

Stecher, C. W., Kallestrup, P., Kjetland, E. F., Vennervald, B. and Petersen, E. (2015). Considering treatment of male genital schistosomiasis as a tool for future HIV prevention: a systematic review. *International Journal of Public Health* **60**, 839–848.

Steinmann, P., Keiser, J., Bos, R., Tanner, M. and Utzinger, J. (2006). Schistosomiasis and water resources development: systematic review, meta-analysis, and estimates of people at risk. *Lancet Infectious Diseases* **6**, 411–425.

Stothard, J. R., Stanton, M. C., Bustinduy, A. L., Sousa-Figueiredo, J. C., Van Dam, G. J., Betson, M., Waterhouse, D., Ward, S., Allan, F., Hassan, A. A., Al-Helal, M. A., Memish, Z. A. and Rollinson, D. (2014). Diagnostics for schistosomiasis in Africa and Arabia: a review of present options in control and future needs for elimination. *Parasitology* **141**, 1947–1961.

WHO (2010). Schistosomiasis. Fact Sheet No. 115, February 2010. (<http://www.who.int/mediacentre/factsheets/fs115/en/>). Accessed 23 June 2015.

WHO (2015). *Female Genital Schistosomiasis: a Pocket Atlas for Clinical Health Professionals*, p. 49. WHO, Geneva. ISBN: 9789241509299.

WHO (2016). Schistosomiasis and soil-transmitted helminthiases: number of people treated in 2015. *Weekly Epidemiological Record* **91**, 585–600.