

Short Communications

Laurent Fradet takes responsibility for the integrity of the content of the paper.

Presented at the Annual Meeting of the Canadian Society of Otolaryngology – Head and Neck Surgery (2016, Charlottetown, Canada) and the Quebec's Annual Otolaryngology – Head and Neck Surgery Association Meeting (2016, Montreal, Canada).

Cite this article: Costisella J, Belzile M, Fortier P-H, Fradet L. Scapular tip free flap reconstruction of complex midface defects using electromagnetic navigation. *J Laryngol Otol* 2025;1–5. <https://doi.org/10.1017/S002221512510248X>

Received: 16 October 2024

Revised: 17 January 2025

Accepted: 22 January 2025



Keywords:

free tissue flaps; scapula; reconstructive surgical procedures; surgical oncology; surgery; computer-assisted; surgical navigation systems

Corresponding author: Laurent Fradet;
Email: Laurent.Fradet@USherbrooke.ca

© The Author(s), 2025. Published by Cambridge University Press on behalf of J.L.O. (1984) LIMITED. This is an Open Access article, distributed under the terms of the Creative Commons Attribution-NonCommercial-ShareAlike licence (<http://creativecommons.org/licenses/by-nc-sa/4.0>), which permits non-commercial re-use, distribution, and reproduction in any medium, provided the same Creative Commons licence is used to distribute the re-used or adapted article and the original article is properly cited. The written permission of Cambridge University Press must be obtained prior to any commercial use.

Scapular tip free flap reconstruction of complex midface defects using electromagnetic navigation

Jérôme Costisella¹ , Mathieu Belzile^{1,2,3}, Pierre-Hugues Fortier^{1,2} and Laurent Fradet^{1,2,3} 

¹Faculty of Medicine, Université de Sherbrooke, Sherbrooke, QC, Canada; ²Division of Otolaryngology – Head and Neck Surgery, Department of Surgery, CIUSSS de l'Estrie - CHUS, Sherbrooke, QC, Canada and ³Institut de recherche sur le cancer de l'Université de Sherbrooke, Sherbrooke, QC, Canada

Abstract

Problem. The virtues of the scapular tip free flap for reconstruction of complex midface oncologic defects have been claimed by many. To obtain optimal functional and aesthetic results, precise positioning of the free flap used for reconstruction is paramount.

Methods. Four cases illustrate our approach to midface reconstruction with angular branch-based scapular tip flaps. A standard surgical navigation device was used both to plan bone cuts for the oncologic resection and to optimise the positioning of the flap.

Results. Case 1 illustrates the usefulness of navigation for reconstruction of total palato-septectomy defects, using a horizontally positioned flap. Optimal neo-palate height, alignment of the anterior nasal spine and nasal projection were obtained. For cases 2–4, vertical inset of the flap yielded optimal midface projection and orbital floor position.

Conclusion. Surgical navigation systems are useful adjuncts for midface reconstruction.

Introduction

Composite midface oncologic defects are among the most challenging reconstructive cases, as optimal aesthetic and functional results strongly rely on the precision of the reconstruction. For ideal results, two conditions must be met: the substrate used for reconstruction must be adequate and positioning of the substrate must be extremely precise.

Regarding selection of the optimal substrate, the virtues of the angular branch-based scapular tip free flap have been claimed by many. Specifically, its long pedicle, its anatomic similarity with the hard palate and the rapid re-epithelialisation of its muscular surface are definite advantages.¹ Moreover, the possibility of dental implantation has been demonstrated for this flap,² and it is possible to proceed to greenstick osteotomies to use different angulations of bone for different components.³

As for optimising positioning of the free flap, surgical navigation devices are a subject of particular interest. Use of intraoperative electromagnetic or infrared image guidance is well established for sinus surgery.⁴ In head and neck surgery, it has been particularly used for intraoperative control of resection margins for advanced tumours⁵ and to guide craniofacial approaches for anterior skull base oncologic surgeries.⁶ In reconstructive surgery, a growing literature supports its use for guiding complex reconstructions. While the existing literature is mostly centred on its use for orbital floor reconstructions and the preparation of osteotomies, some authors have used navigation specifically for refining the positioning of peroneal⁷ and latissimus dorsi⁸ free flaps for midface reconstructions.

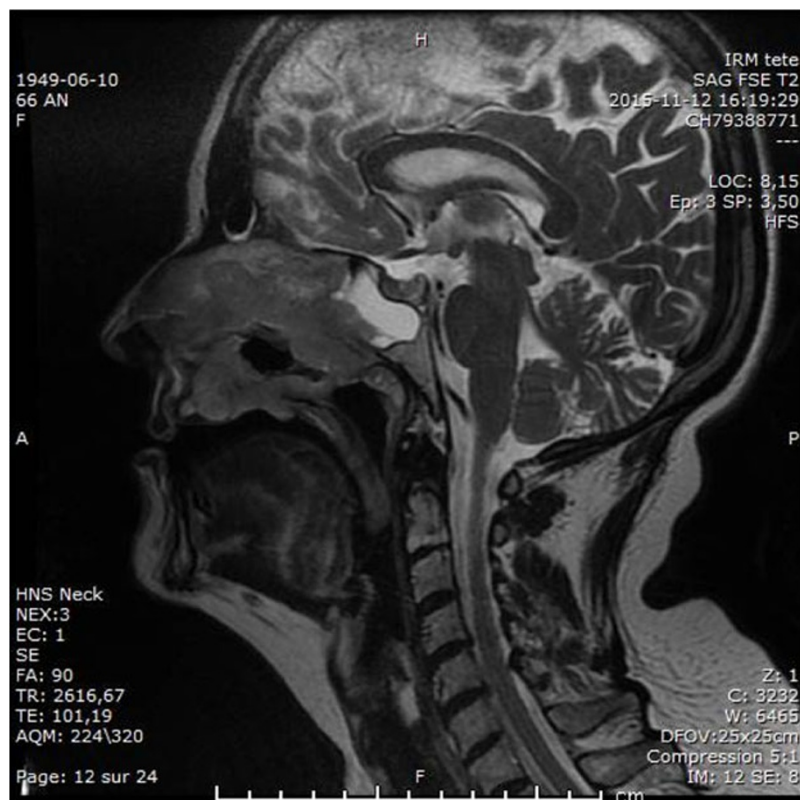
We developed an approach for reconstruction of complex midface defects combining angular branch-based scapular tip free flaps and electromagnetic navigation in an innovative way. In our opinion, this method yields optimal aesthetic and functional outcomes. We hereby present a summary of our approach, illustrated by four clinical cases.

Material and methods

Participants

Patients operated at the Centre Intégré Universitaire de Santé et de Services Sociaux de l'Estrie – Centre Hospitalier Universitaire de Sherbrooke (CIUSSS de l'Estrie – CHUS) for midface malignancies using the combination of a surgical navigation device and an angular branch-based

Figure 1. T2 sagittal MRI demonstrating a squamous cell carcinoma of the nasal septum with extension to the hard palate, ethmoids and sphenoid sinuses (patient #1).



scapular tip free flap reconstruction were seen at regular follow up according to National Comprehensive Cancer Network (NCCN) guidelines. Patients were contacted for consent and their files were retrospectively studied to collect the data presented in this series.

Materials

A conventional electromagnetic surgical navigation system was used for every case (Fusion ENT Navigation System, Medtronic, Minneapolis, Minnesota). To enable mobility of the head during surgery without restricting the surgical access, a reference system, consisting of a Cranial Dynamic Fixation Frame (Medtronic, Minneapolis) was fixed to the patient's skull. This system, although more expensive than the standard surface sticker registration, is more precise and more versatile, as it can be installed anywhere on the calvarium and thus does not interfere with craniofacial resections.

Surgical technique

For every case, a pre-operative computed tomography (CT) scan and magnetic resonance imaging of the facial bones with navigation protocol sequences, as for computer-assisted sinus surgery, were obtained and downloaded in the electromagnetic navigation device (Figure 1).

At the beginning of the surgery, the electromagnetic device is draped and positioned freely at the head of the patient, for easy access throughout the case. The reference device is installed, and calibration is undertaken according to the manufacturer's protocol (Figure 2). During the resection, the navigation device may be used in establishing appropriate cuts in remote bony margins, notably at the level of the pterygoid plates.

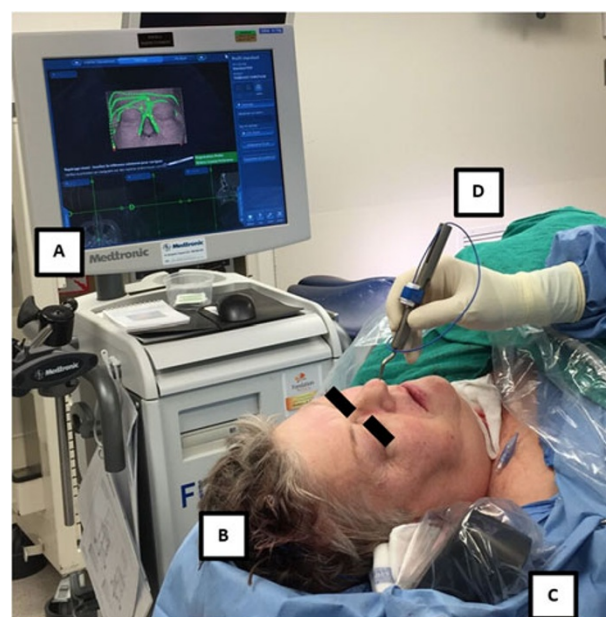


Figure 2. Operative setup for patient #1. The navigation system (A) is positioned at the head of the patient. The reference system, a Cranial Dynamic Fixation Frame (B) Medtronic, Minneapolis, has been fixed to the patient skull. The electromagnetic emission device (C) is draped and positioned freely at the head of the patient, for easy access during surgery. The device pointer (D) is used for calibration of the navigation system at the beginning of the surgery.

To harvest the angular branch based-scapular tip free flap, a triangular cushion is positioned under the lateral thorax before draping of the donor site side, thus exposing the scapula upon tilting of the table. The muscular triangle delimited by the teres major,

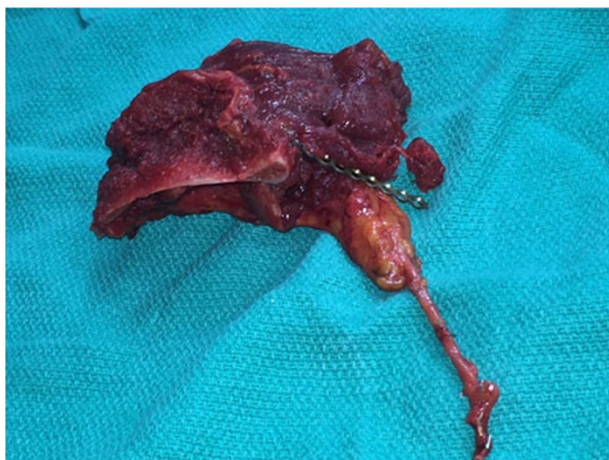

Figure 3. Scapular tip free flap for palatal reconstruction (patient #1). Reconstruction plates are fixed posteriorly to the scapular tip free flap. In this situation, the flap has been positioned horizontally to reconstruct a total palatal defect. The anatomic similarity of this flap with the bony palate, along with the rapid reepithelialization of its muscular surface, make it an ideal option for such reconstructions. Also depicted is the significant pedicle length of this flap.

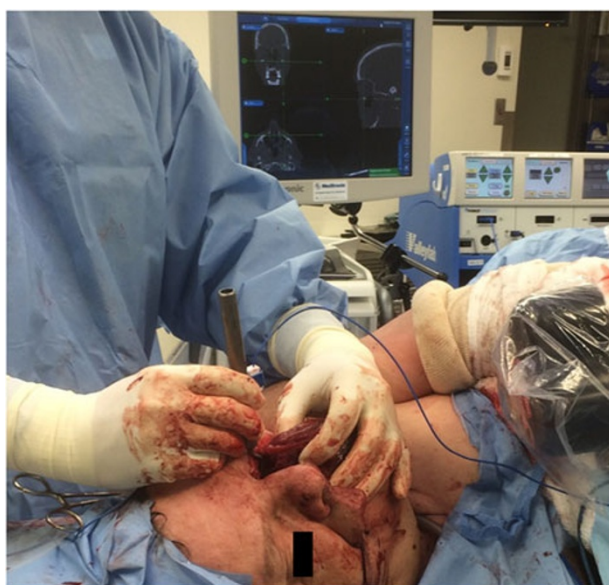

Figure 4. Operative use of the navigation system for optimal positioning of the free flap (patient #3).

teres minor and triceps is palpated, and a curvilinear incision is made from the triangle inferiorly to incorporate the tip of the scapula. Exposition and inferior retraction of the latissimus dorsi muscle shows the intermuscular septum between the latissimus dorsi and teres major. Further dissection enables identification of the thoracodorsal artery after dividing the teres major, giving off the angular artery, which is followed to its entry point at the tip of the scapula on its lateral aspect. The appropriate amount of bone is resected, and the vascular pedicle is followed all the way to the origin of the subscapular artery (Figure 3).

During the inset of the flap, surgical navigation is used to match the position of the flap with pre-existent anatomic bony landmarks (Figure 4).

Results and analysis

Table 1 describes the cases and the utility of neuronavigation for each one of the four cases. Figure 5 depicts post-operative results for patient 1.

Discussion

As described by Santamaria,⁹ maxillectomy defects present three specific reconstructive challenges: (1) restoration of an adequate orbital support, (2) restoration of the oronasal separation and of the functional aspects of both elements, and (3) reestablishment of the facial contour. The four cases presented in this article reflect all these challenges.

Angular branch-based scapula tip free flaps are both reliable and versatile for midface reconstruction.¹ Their versatility allows for optimal adaptation to the deficit, with both vertical and horizontal positioning being possible, depending on the architecture of the osteotomies. No complications specifically related to the flap have been encountered in this series.

As suggested by Feinchtenger *et al.*,⁵ navigation is helpful in assessing the bony margins of resection, which are often challenging for midface. In all these cases, navigation also allowed optimal positioning of the scapular tip free flaps. This tool has been particularly useful for securing the height of the reconstructed palate and the alignment of the nasal spine, evaluating nasal and malar projection, and assessing orbital floor position for reconstruction of total maxillectomy defects. A typical pitfall is to base the appreciation of a reconstruction on the appearance of overlying soft tissues. Because most head and neck cancer patients will undergo adjuvant post-operative radiotherapy, it is predictable that significant modifications and resorption of the soft tissues will occur. Such a situation may often lead to good immediate post-operative aesthetic results, which will, however, decline in the longer term. Navigation-assisted bony reconstruction of midface defects allows for precise free flap positioning and compensation for the expected post-radiation soft tissue volume variations.

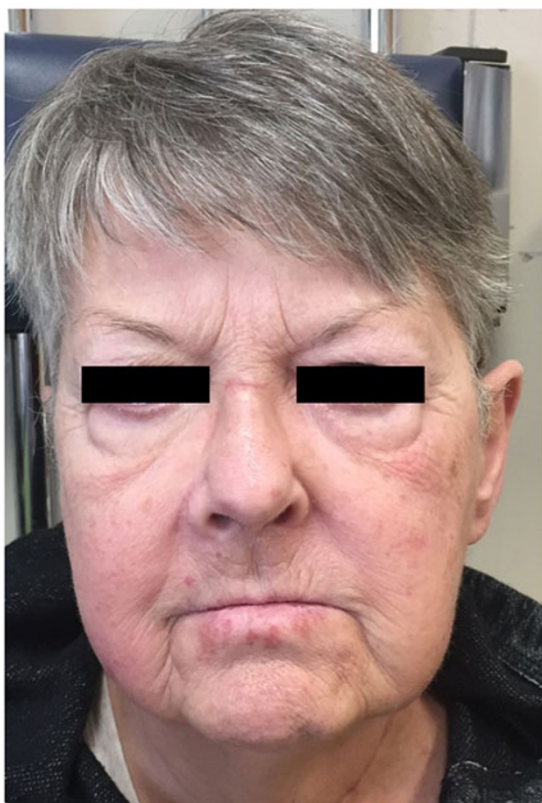Previously published studies concerning the use of surgical navigation to guide various reconstructions have come to similar conclusions. Harbison *et al.*,¹⁰ compared mandibular alignment following segmental mandibulectomy on cadavers using surgical navigation, surgical templates and freehand techniques. Surgical navigation proved to be similar to template-guided reconstruction, but with the added benefit of permitting real-time adjustment independently of the initial resection and reconstruction plans, and was superior to freehand reconstruction.

The use of computer-assisted design with pre-operative 3D printing has gained popularity in the recent decades. However, computer-assisted designs require additional time for pre-operative virtual planning and involves a significant learning curve for the surgeon.¹¹ Furthermore, computer-assisted design incurs costs exceeding up to \$10,000 per case and models cannot be adjusted if cutting guides are incorrectly positioned or if resection margins need updating during the case.¹⁰ In our hospital, current prices are between \$3,300 and \$3,700 Canadian per case for 3D planning, whereas the neuronavigation equipment costs approximately \$790 Canadian per case (Instrument Tracker (wire) – Navigation-Fusion: \$150; Cranial Navigation Tracker (screw) – Navigation-Fusion: \$640).

Since navigation-assisted functional endoscopic sinus surgery has become the standard of care in many situations,⁴ navigation

Table 1. Summary of our case series of complex midface reconstruction with scapular tip free flaps and surgical navigation device

Identification	Pathology	Defect	Positioning of the flap	Utility of the navigation system
PATIENT #1: ♀, 66 years old	Nasal septum squamous cell carcinoma with sphenoethmoidal extension and hard palate erosion (T _{4a} N ₀ M ₀ ; Figure 1)	Total palato-septectomy with anterior ethmoidectomy	Horizontal (Figure 3)	Assessment of bony margins of resection Positioning of the reconstructed nasal spine and neo-palate (Figure 5)
PATIENT #2: ♂, 63 years old	Recurrent polymorphous adenocarcinoma of the oral cavity with extension to maxillary sinus and pterygoids (T _{4b} N ₀ M ₀)	Subtotal maxillectomy	Vertical; provides support to the titanium orbital floor reconstruction mesh. Placement of the thicker lateral scapula border inferiorly to recreate the maxillary crest, the thinner portion extending medially towards the piriform aperture.	Precise positioning of the flap according to the pre-operative location of the bony edges of the nasal spine, the cheek, and the inferior orbital rim
PATIENT #3: ♂, 73 years old	Left cheek squamous cell carcinoma with zygomatic extension (T ₃ N _{2b} M ₀)	Subtotal maxillectomy, with orbital floor and zygomatic resection	Same as patient #2	Same as patient #2
PATIENT #4: ♀, 57 years old	High grade conventional osteoblastic and chondroblastic osteosarcoma of the left maxillary sinus, with extension to the skin anteriorly, pterygoid musculature posteriorly, anterior fossa superiorly, and orbit medially	Total maxillectomy with resection of anterior fossa skull base	Same as patient #2	Assessment of optimal cheek projection and neo-alveolar ridge positioning

**Figure 5.** Postoperative result for patient #1.

equipment is often readily available for the reconstructive surgeon. In our experience, the few minutes spent calibrating the machine are more than made up by the expedited flap positioning. We have found that the use of a stand for the electromagnetic device, such as in functional sinus surgery, is not practical. Therefore, we have

elected to drape the electromagnetic device in a sterile fashion and move it near the midface whenever a reading is needed.

The principal caveat that has been encountered in our experience is the tendency for the navigation device to decalibrate throughout surgery. The causes of these decalibrations, which have been discussed by Sorriento *et al.*,¹² include metal and ferromagnetic sources in the operating theatre, such as nearby cell phones. This remains, however, unusual. Calibration of the instruments should be verified periodically throughout the case using reliable anatomical landmarks in proximity to the resection site, such as the glabella and lateral orbit, and the instruments should be recalibrated if required.

- Scapular tip flaps provide versatile and reliable tissues for complex midface defects.
- Surgical navigation facilitates accurate positioning of free flaps, with real-time adjustments accommodating variations in patient anatomy, thus optimising aesthetic and functional outcomes.
- Proper calibration and verification of navigation systems is essential to optimise accuracy throughout surgery.
- Surgical navigation minimises additional costs compared to other advanced imaging and planning technologies, making it a cost-effective option for complex midface reconstructions.

Conclusion

Judging from our practice, optimal results for complex midface reconstructions can be obtained by combining the intrinsic advantages of the angular branch-based scapular tip free flap with the use of a surgical navigation system. In our opinion, the minimal additional operative time and low cost justify its integration to assist in reconstruction of complex craniofacial defects.

Funding. The authors have no financial interest or commercial association with any of the subject matter or products mentioned in this manuscript.

References

- 1 Piazza C, Paderno A, Taglietti V, Nicolai P. Evolution of complex palatomaxillary reconstructions: the scapular angle osteomuscular free flap. *Curr Opin Otolaryngol Head Neck Surg* 2013;**21**:95–103
- 2 Tang AL, Bearely S, Mannion K. The expanding role of scapular free-flaps. *Curr Opin Otolaryngol Head Neck Surg* 2017;**25**:411–15
- 3 Haring CT, Marchiano EJ, Stevens JR, Malloy KM, Casper KA, Prince ME, *et al.* Osteotomized folded scapular tip free flap for complex midfacial reconstruction. *Plast Aesthet Res* 2021;**8**:33
- 4 American Academy of Otolaryngology-Head and Neck Surgery (AAO-HNS). Position Statement: Intra-Operative Use of Computer Aided Surgery. In: <https://www.entnet.org/resource/position-statement-intra-operative-use-of-computer-aided-surgery/> [30 June 2024]
- 5 Feichtinger M, Pau M, Zemmann W, Aigner RM, Kärcher H. Intraoperative control of resection margins in advanced head and neck cancer using a 3D-navigation system based on PET/CT image fusion. *J Craniomaxillofac Surg* 2010;**38**:589–94
- 6 Nakamura M, Stöver T, Rodt T, Majdani O, Lorenz M, Lenarz T, *et al.* Neuronavigational guidance in craniofacial approaches for large (para)nasal tumors involving the anterior skull base and upper clival lesions. *Eur J Surg Oncol* 2009;**35**:666–72
- 7 Hanasono MM, Jacob RF, Bidaut L, Robb GL, Skoracki RJ. Midfacial reconstruction using virtual planning, rapid prototype modeling, and stereotactic navigation. *Plast Reconstr Surg* 2010;**126**:2002–6
- 8 Kokemueller H, Tavassol F, Rücker M, Gellrich NC. Complex midfacial reconstruction: a combined technique of computer-assisted surgery and microvascular tissue transfer. *J Oral Maxillofac Surg* 2008;**66**:2398–406
- 9 Santamaria E, Cordeiro PG. Reconstruction of maxillectomy and midfacial defects with free tissue transfer. *J Surg Oncol* 2006;**94**:522–31
- 10 Harbison RA, Shan XF, Douglas Z, Bevans S, Li Y, Moe KS, *et al.* Navigation guidance during free flap mandibular reconstruction: a cadaveric trial. *JAMA Otolaryngol Head Neck Surg* 2017;**143**:226–33
- 11 Sozzi D, Filippi A, Canzi G, De Ponti E, Bozzetti A, Novelli G. Surgical navigation in mandibular reconstruction: accuracy evaluation of an innovative protocol. *J Clin Med* 2022;**11**:2060
- 12 Sorriento A, Porfido MB, Mazzoleni S, Calvosa G, Tenucci M, Ciuti G, *et al.* Optical and electromagnetic tracking systems for biomedical applications: a critical review on potentialities and limitations. *IEEE Rev Biomed Eng* 2020;**13**:212–32