

Failure to post-dilate BeSmooth peripheral stents to adult vessel size diameters during benchside tests

Original Article

Cite this article: Haddad RN, Bonnet D, and Malekzadeh-Milani S (2023) Failure to post-dilate BeSmooth peripheral stents to adult vessel size diameters during benchside tests. *Cardiology in the Young* **33**: 2597–2603. doi: [10.1017/S1047951123000720](https://doi.org/10.1017/S1047951123000720)

Received: 24 January 2023
Revised: 1 March 2023
Accepted: 15 March 2023
First published online: 19 April 2023

Keywords:

Benchside test; children; CHD; stent interventions

Address for correspondence:

Dr R. N. Haddad, MD, Service de cardiologie congénitale et pédiatrique, centre de référence des malformations cardiaques congénitales complexes - M3C, Hôpital Universitaire Necker-Enfants malades, Assistance Publique-Hôpitaux DE Paris, 149, rue de Sèvres, 75015, Paris, France. Tel: +33 1 44 49 80 50; Fax: +33 1 44 49 47 30. E-mail: raymondhaddad@live.com

Raymond N. Haddad¹ , Damien Bonnet^{1,2}  and Sophie Malekzadeh-Milani¹ 

¹M3C-Necker, Hôpital Universitaire Necker-Enfants malades, Assistance Publique-Hôpitaux de Paris (AP-HP), Paris, France and ²Université de Paris Cité, Paris, France

Abstract

Background: Low-profile stent implantation remains a rescue treatment for aortic coarctation and branch pulmonary arteries stenosis in small children. Stent re-expansion to cope with vascular growth remains problematic. **Objectives:** To evaluate ex vivo feasibility and mechanical behaviour of over-dilating BeSmooth peripheral stents (Bentley InnoMed, Germany). **Methods:** Three BeSmooth peripheral stents in diameters of 7, 8, and 10 mm were dilated to nominal pressure and then 13 atm. BeSmooth Ø7 × 23 mm was sequentially post-dilated using 12, 14, and 16 mm high-pressure balloons. BeSmooth Ø10 × 57 mm was post-dilated with a 14 mm balloon and then with a 48 mm bare-metal Optimus XXL stent hand-mounted on a 14 mm balloon (stent-in-stent). BeSmooth Ø8 × 57 mm was directly post-dilated with a 48 mm bare-metal Optimus XXL stent hand-mounted on a 16 mm balloon (stent-in-stent). The stents' diameter and length were measured. Digital inflation pressure was noted. Balloon rupture and stent fracture patterns were closely evaluated. **Results:** At 20atm pressure, BeSmooth Ø7 × 23 mm shortened to 2 mm forming a 12 mm diameter solid ring circle and the woven balloon ruptured radially. At 10 atm pressure, BeSmooth Ø10 × 57 mm fractured longitudinally in various dispatched breaking points at a diameter of 13 mm without shortening and ruptured the balloon with multiple pinholes. At 10 atm pressure, BeSmooth Ø8 × 57 mm fractured centrally at three different points at a diameter of 11.5 mm without shortening and the balloon broke radially in half. **Conclusions:** In our benchmark tests, extreme shortening, severe balloon rupture, or unpredictable stent fracture patterns at small balloon diameters limits safe post-dilation of BeSmooth stents beyond 13 mm. BeSmooth stents are not ideal candidates for off-label stent interventions in smaller patients.

Introduction

Transcatheter stent implantation into growing vessels is an essential minimally invasive treatment option in infants and small children with CHD and corresponding vascular stenotic lesions.^[1–5] After stent implantation in small children, serial stent re-expansion is frequently necessary to keep pace with somatic growth^[1,3,5]. Concerns exist regarding the creation of fixed obstructions secondary to the stent if expansion to larger diameters over time is not possible. Until now, there are no endovascular stents designed for or approved for use in infants, nor is there a stent capable of being implanted at infant vessel diameters and achieving adult size while maintaining structural integrity. Most tested low-profile coronary or peripheral stents have limited finite maximum expansion diameters. Depending on the design of the stent, further over-dilations using ultra-high-pressure angioplasty balloons will result either in extreme stent shortening or intentional stent fracture with the potential loss of radial strength^[6,7]. Therefore, stent therapy in growing infants remains problematic, making surgical explantation or complex re-stenting procedures necessary during further growth^[8,9]. Despite various design limitations, Cook Formula and Bard Valeo peripheral stents are the most commonly used stents for this off-label approach with reasonably acceptable results^[1–5]. Both of these stents are no longer easy to have on the European market, and it is crucial to find alternatives. BeSmooth stents (Bentley InnoMed, Germany) are low-profile, pre-mounted, balloon-expandable, bare-metal, open-cell-designed peripheral stents. These stents have been also used infrequently in the off-label treatment of small patients with native or recurrent aortic coarctation and native or post-surgical branch pulmonary arteries stenosis. Long-term outcomes of these stents as well as safety and performance during re-dilatation have not been reported in the literature. Herein, we evaluate the *ex vivo* feasibility of post-dilating BeSmooth peripheral stents into adult vessel size diameters. We also describe the mechanical behaviour of BeSmooth stents during multiple-stage sequential re-dilations and stent-in-stent re-dilatation approach.

Methods

Setting and setup

The *ex vivo* benchside testing of BeSmooth peripheral stent systems was carried out in the digital biplane catheterisation laboratory (Artis zee system, Siemens, Germany) of our institution. According to the local guidelines, there was no need for the permission of the institutional review board because no patient data were used. The tests were done in a sterile environment and in the absence of any member or representative of the manufacturing companies. Balloon inflation was done with a Monarch[®] inflation device (20 cc/ml barrel – 30 atm/bar) (Merit Medical Systems, Inc., USA), and digital inflation pressure was noted at each balloon inflation. Nominal expansion and post-dilatations of the stents were recorded with continuous biplane cine-fluoroscopy. Balloons were completely deflated after achieving the inflation pressure. Biplane X-ray single-frame shots were acquired after each stent dilation for fluoroscopic stent measurements. Calibration was performed before each measurement. Direct stent measurements were also done meticulously using a 6-Inch/15 cm Vinyl plastic ruler (GRI, China).

BeSmooth peripheral stent systems

The BeSmooth peripheral stent systems are over-the-wire (0.035-Inch), pre-mounted, balloon-expandable, bare-metal stents. The stents are indicated for the treatment of de novo or re-stenotic, atherosclerotic lesions in protected peripheral arteries offering high radial force, flexibility, and low profile. BeSmooth stents are made of Cobalt-Chromium (L605) with an open-cell design. The stent exists in three versions (SV, MV, and LV) that differ slightly by the width of the strut (0.135, 0.145, and 0.165 mm, respectively), while the thickness of the strut is 0.145 mm for the three versions. Each stent version is recommended to be inflated according to the nominal diameter of the balloon upon which the stent is pre-mounted. The expanded stent-graft diameters are 5.0 and 6.0 mm for the SV, 7.0 and 8.0 mm for the MV, and 9.0 and 10.0 mm for the LV model. Each stent version is available in five nominal lengths, starting from 18 mm and moving up to 57 or 58 mm (18, 23, 27–28, 38, or 57–58 mm). The nominal and rated burst pressures of the semi-compliant balloon carriers are 10 and 13 bars for stents with a diameter of 5–6 mm, and 8 and 12 bars for stents with a diameter of 7–10 mm, respectively. All sizes are compatible with 6-Fr introducer sheaths. The catheter shaft size is 5-Fr with a 75 cm /120 cm length.

Benchmark testing rationale, protocol, and measurements

The rationale of the study protocol was to test three different scenarios of redo interventions on BeSmooth peripheral stents implanted at vessel diameters of small patients. The three scenarios are sequential upsizing post-dilation without re-stenting (test 1), post-dilation until plateau/breakpoint followed by re-stenting (test 2), and finally, straightforward re-stenting (test 3). The MV and LV versions of the stent are almost similar. Both of these stent versions are suitable for treating vessels with diameters ranging from ≥ 6 to 10 mm. The assignment of each stent to each scenario was random.

Over a 0.035-inch/260 cm stiff wire, three sterile samples of BeSmooth peripheral stents with nominal diameters of 7, 8, and 10 mm were initially expanded by inflating their balloon carriers to nominal pressure and then to 13 atm. *Test 1:* BeSmooth stent $\text{\O}7 \times 23$ mm was sequentially post-dilated using $\text{\O}12 \times 40$ mm and $\text{\O}14 \times 40$ mm Armada 35 (Abbott Vascular, USA) and then

$\text{\O}16 \times 40$ mm Atlas[®] Gold (Bard Peripheral Vascular, Inc., USA) non-compliant ultra-high-pressure angioplasty balloon catheters. *Test 2:* BeSmooth stent $\text{\O}10 \times 57$ mm was post-dilated using an $\text{\O}14 \times 40$ mm Armada 35 (Abbott Vascular, USA) angioplasty balloon catheter. Subsequently, BeSmooth stent $\text{\O}10 \times 57$ mm was re-dilated with a 48 mm-long bare-metal Optimus[®] XXL stent (AndraTec, Germany) hand-mounted over another $\text{\O}14 \times 40$ mm Armada 35 angioplasty balloon in an attempt to expand the BeSmooth stent $\text{\O}10 \times 57$ mm to a minimum diameter of 14 mm (stent-in-stent). *Test 3:* BeSmooth stent $\text{\O}8 \times 57$ mm was post-dilated directly with a 48 mm-long bare-metal Optimus[®] XXL stent (AndraTec, Germany) hand-mounted over a $\text{\O}16 \times 40$ mm Altosa-XL (AndraTec, Germany) angioplasty balloon in an attempt to expand the BeSmooth stent $\text{\O}8 \times 57$ mm to a diameter of 16 mm (stent-in-stent).

Direct and anteroposterior fluoroscopic relevant measurements of the diameter and length of the inflated stents were performed at each step. Balloon rupture was recorded and described. We classified balloon rupture into pinhole tears and complete or partial, radial, or horizontal tear lines.

We paid attention to audible stent cracks. The stents were closely inspected in direct view and on X-ray acquisitions to count the struts fracture and evaluate the stent distortion and fracturing patterns. We classified stent fractures as complete longitudinal fractures if there was clear evidence of disruption of each of the struts along the stent's entire length and partial longitudinal fractures if the struts were disrupted along a portion of the stent. Circumferential stent fractures are fractured connections between stent rings with the rings themselves remaining circumferentially intact along the length of the stent.

Results

The results of the benchside tests of the BeSmooth peripheral stents with nominal diameters of 7, 10, and 8 mm are outlined in Tables 1, 2 and –3, respectively.

Test 1: The BeSmooth stent $\text{\O}7 \times 23$ mm can be post-dilated to 10 mm diameter with a little shortening. Upsizing the stent to 11 mm with an Armada 35 balloon $\text{\O}14$ mm led to the stent shrinking to 3.2 mm (Table 1, Fig 1). It was impossible to post-dilate the BeSmooth $\text{\O}7 \times 23$ mm beyond a diameter of 12 mm because the Atlas Gold $\text{\O}16$ mm balloon exploded at an inflation pressure of 20 atm. At last, BeSmooth $\text{\O}7 \times 23$ mm shortened to 2 mm (Fig 2a) forming a 12 mm-large solid ring circle with overlapping struts (Fig 2b). There was a half-circular radial tear line within the Atlas Gold balloon (Fig 2c). We did not hear any stent cracks or visually identified struts fracture on direct or X-ray inspections. Manual inspection of the ring circle revealed an inward sharper protrusion of the overlapped struts.

Test 2: BeSmooth $\text{\O}10 \times 23$ mm was expanded with progressive pressure inflation of the Armada 35 balloon $\text{\O}14$ mm. We stopped the inflation at a pressure of 10 atm when we heard two stent cracks (Fig 3). The BeSmooth $\text{\O}10 \times 23$ mm reached a diameter of 13 mm without shortening and the balloon did not rupture. A bare-metal 48 mm-long Optimus XXL stent mounted on an Armada 35 balloon $\text{\O}14$ mm was re-expanded inside the BeSmooth $\text{\O}10 \times 23$ mm stent. The inflation was stopped at a pressure of 10 atm because BeSmooth $\text{\O}10 \times 23$ mm was severely fractured at a diameter of 13 mm, and the balloon was ruptured at multiple points with subsequent loss of inflation pressure (Fig 4a and b). We noticed complete circumferential straightening of the stent zigs just

Table 1. Benchside test results with BeSmooth stent $\varnothing 7 \times 23$ mm

Balloon	IP (atm)	Length (mm)		\varnothing (mm)		Stent fracture	Balloon rupture
		Direct View	Fluoroscopy AP	Direct view	Fluoroscopy AP		
Stent balloon carrier	8 (NP)	–	21	6.3	5.95	No	No
Stent balloon carrier	13	22	21.57	6.5	6.95	No	No
Armada 35 12x40mm (Abbott Vascular)	15	20	19.39	10	9.69	No	No
Armada 14x40mm (Abbott Vascular)	15	3.2	3.72	11	11	No	Two pinpoint tears
Atlas Gold 16x40mm (Bard Peripheral Vascular)	4	–	–	–	–	No	No
	8	–	–	–	–	No	No
	20	2	1.96	12	11.92	No	Half radial tear line

AP = anteroposterior; atm = atmospheres; IP = inflation pressure; NP = nominal pressure; \varnothing = diameter.

Table 2. Benchside test results with BeSmooth stent $\varnothing 10 \times 57$ mm

Balloon	IP (atm)	Length (mm)		\varnothing (mm)		Stent fracture	Balloon rupture
		Direct view	Fluoroscopy AP	Direct view	Fluoroscopy AP		
Stent balloon carrier	8 (NP)	–	54.14	9.2	9.54	No	No
Stent balloon carrier	13	57	56.54	10	10.2	No	No
Armada 14x40mm (Abbott Vascular)	10	60.5	61.99	13	13.41	Two cracks	No
Armada 14x40mm + BMS Optimus XXL 48mm	10	–	–	13	–	Multiple dispatched cracks	Multiple pinpoint tears

AP = anteroposterior; atm = atmospheres; IP = inflation pressure; BMS = bare-metal stent; NP = nominal pressure; \varnothing = diameter.

Table 3. Benchside test results with BeSmooth stent $\varnothing 8 \times 57$ mm

Balloon	IP (atm)	Length (mm)		\varnothing (mm)		Stent fracture	Balloon rupture
		Direct view	Fluoroscopy AP	Direct view	Fluoroscopy AP		
Stent balloon carrier	8	–	–	–	–	No	No
Stent balloon carrier	13	57	56.52	7.5	7.76	No	No
AltoSa-XL 16x40mm + BMS Optimus XXL 48mm	3	–	–	–	–	No	No
	10	–	–	11.5	11.83	Three cracks	Full radial tear line

AP = anteroposterior; atm = atmospheres; BMS = bare-metal stent; IP = inflation pressure; NP = nominal pressure; \varnothing = diameter.




Fig. 1 Anteroposterior X-ray acquisitions shots of sequential upsizing high-pressure balloon inflation of the BeSmooth stent $\varnothing 7 \times 23$ mm (a, b, c). Note the stent shortening and the fixed stent diameter.

before the stent fractured. The stent was distorted completely when re-inspected carefully with the separation of the stent rings at the point of longitudinal fracture with radial fracture lines and protrusion of the fractured ends within the stent circles (Fig 5a and b).

Test 3: Bare-metal 48 mm-long Optimus XXL stent was mounted on an AltoSa-XL angioplasty balloon $\varnothing 16$ mm and was expanded progressively inside the BeSmooth $\varnothing 8 \times 57$ mm until the balloon exploded at an inflation pressure of 10 atm. We heard three stent cracks and identified three fractures of the stent struts (Fig 6a). There was a full circular radial tear line within the AltoSa-XL balloon, and the withdrawal of the balloon distal part was critical (Fig 6b). The stent, however, did not shorten visually.

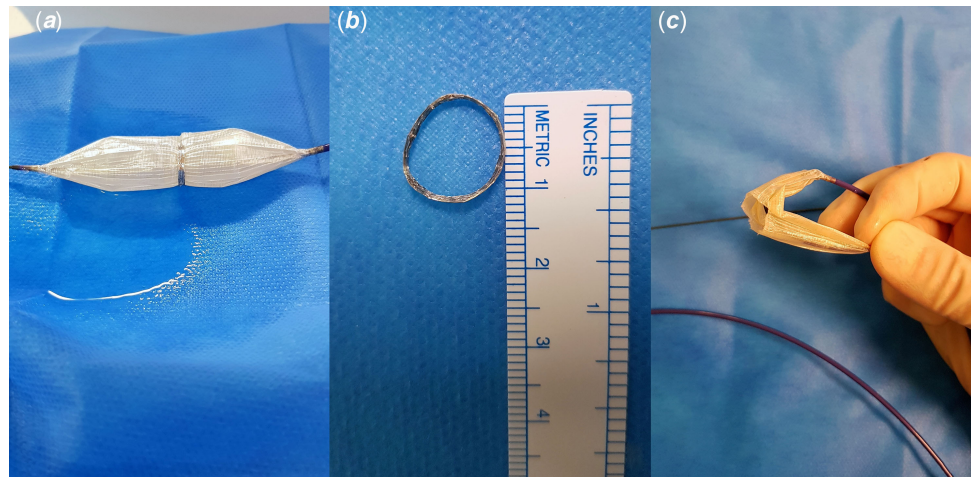


Fig. 2 BeSmooth $\text{\O}7 \times 23$ mm shortening to 2 mm and forming a 12 mm-large solid ring circle with overlapping struts after sequential balloon inflation ending up with an Atlas Gold balloon $\text{\O}16$ mm (**a, b**). Half-circular radial tear line of the woven mesh Atlas balloon with loss of pressure (**c**).

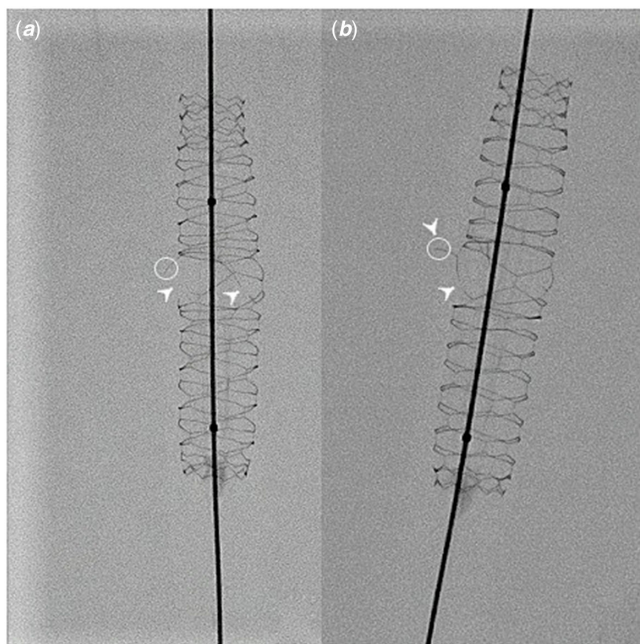


Fig. 3 Anteroposterior (**a**) and lateral (**b**) X-ray acquisitions shots of the BeSmooth $\text{\O}10 \times 23$ mm after progressive expansion with an Armada 35 balloon $\text{\O}14$ mm. Note the two longitudinal fracture lines within the stent occurring in two opposing cells within the most stretched middle section of the stent at a diameter of 13 mm (white pointed arrows). This pattern of fractures induced an outward orientation of the stent struts in different directions (white circles).

Discussion

BeSmooth peripheral stents have been used infrequently in the off-label stent treatment of small patients with various congenital heart lesions. This report is the first to describe the mechanical behaviour of BeSmooth stents when over-dilated to reach adult-size diameters in three different scenarios. In our benchmark test conditions, we showed that excessive stent shortening with overlapping struts, balloon rupture with loss of inflation pressure, or uncontrolled stent fracture patterns at small balloon diameters limit safe and effective post-dilation of BeSmooth stents beyond 13 mm.

Stent implantation remains a controversial strategy in patients below 15 kg due to relatively large sheath sizes and the inability to accommodate adult vessel sizes after somatic growth. Initially, the Palmaz stents and later on the Cook Formula and Bard Valeo

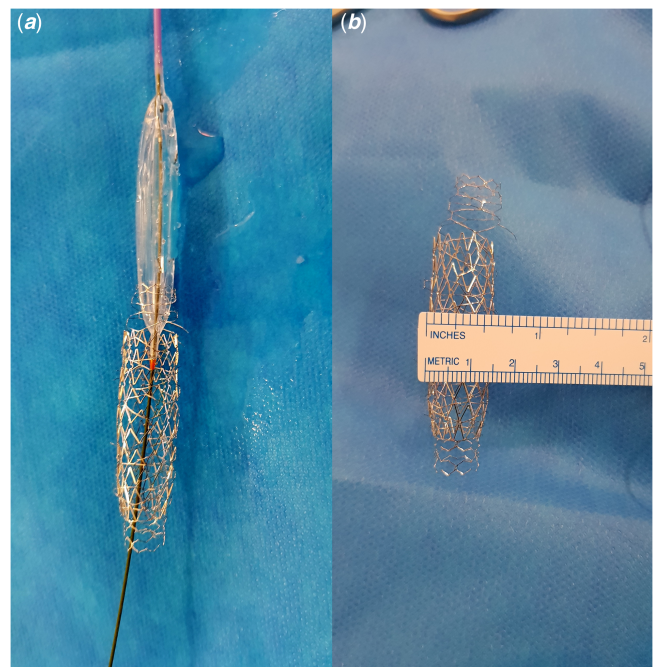


Fig. 4 Severely fractured BeSmooth $\text{\O}10 \times 23$ mm at a diameter of 13 mm when re-expanded with bare-metal 48 mm-long Optimus XXL stent mounted on an Armada 35 balloon $\text{\O}14$ mm (**a, b**). Note the multiple holes within the ruptured Armada balloon and subsequent loss of inflation pressure (**a**).

stents were the most commonly used in this approach because these stents are conformable and easy to deliver, even in small children.^[1–6,10] However, these stents have limited radial strength to prevent vessel recoil, have limited expansion diameters after re-dilations, and lack the potential for controlled stent strut breakage.^[2,3,11] Both Formula and Valeo stents are pre-mounted open-cell stents. However, the Valeo stent has a triple helical architecture and the open cells are larger than the ones in the Formula stent with a “two diamonds” cell design. For that reason, the maximally achievable diameter of the Valeo stents has been reported to be higher than the one achieved by the Formula stents.^[4,12] The BeSmooth open-cell stents also have a triple helical architecture, yet uncontrolled stent shrinking or struts fracture within the cells occurred at lower expansion diameters. We observed that the stent reached its plateau/breakpoint at an inner diameter of 11–12 mm.

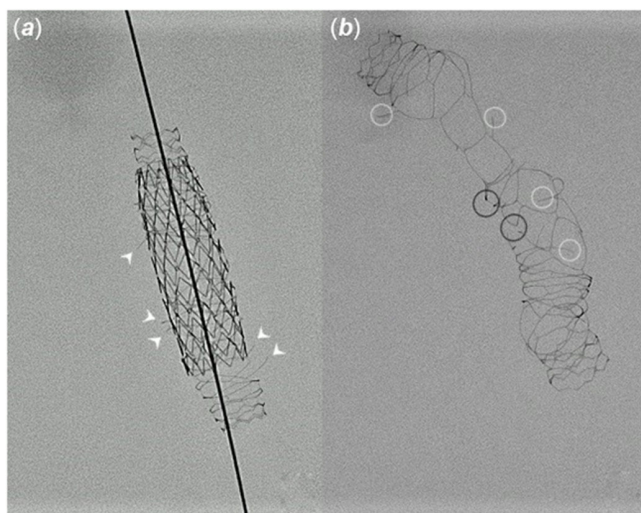


Fig. 5 Anteroposterior X-ray acquisitions shots of the BeSmooth $\varnothing 10 \times 23$ mm after inflation of 48 mm-long Optimus XXL stent and balloon rupture. Note the multiple and dispatched strut fractures with inward and outward orientations (white pointed arrows) (a). Same BeSmooth $\varnothing 10 \times 23$ mm re-inspected after carefully taking out Optimus stent. Note the total stent distortion with radial (connection between cells) (black circles) and longitudinal (within the cell line) (white circles) fracture lines (b).

We observed that no further dilatation was able to occur once the diamond-shaped open cells were elongated into a circular shape because the metal itself is non-stretchable. Expanding the stent above 11–12 mm has led either to the cracking of the stent struts at various points without length shortening or to excessive stent shrinking, and overlapping struts, yet without stent fracture.

Other groups have reported intentional uncontrolled stent breakage of commonly available stents [6,7]. In the process of stent post-dilation, the stress applied to the stent can exceed the ultimate tensile stress limit of the metal and result in an overload stent fracture allowing for further expansion of the vessel lumen. Intentional fracture of the stent using non-compliant ultra-high-pressure balloons has been promoted in a previous study. The authors showed that it can be accomplished across many different stent types with relatively low adverse event rates [6]. However, caution must be taken because this intentional stent breakage can result in protrusion into adjacent vessels [3], an unstable portion of the fractured stent with the need for re-stenting, distal stent fragment embolisation, and even a vascular tear or disruption after stent fracture requiring covered stent placement [6]. We observed in our benchmark tests that most balloon ruptures were explosive and all balloon ruptures led to the loss of inflation pressure. Most ruptures had a radial tear line pattern even within the higher profile Atlas Gold woven mesh balloon. This may lead to the “parachuting” of the distal balloon parts, which then may make re-sheathing and retrieval of the balloon within the distorted stent risky and perhaps impossible [12]. High-pressure-induced balloon rupture during dilation can also result in vessel rupture causing haemoptysis or even hemothorax [6].

In comparison, it has been shown that a Cook Formula stent can reach a maximum diameter of 16 or 18 mm. After that, a “stent-in-stent” breaking procedure can be performed with a covered stent inside and an Atlas balloon of 18 or 20 mm [5]. The authors showed that a controlled longitudinal fracturing with little foreshortening and preservation of the circular shape can be achieved in vitro with an Atlas balloon not more than 2–4 mm larger than the Formula stent. Although in vivo stent breaking

has not been indicated in the series of patients with recurrent aortic coarctation, van Kalsbeek et al. report that it has been performed successfully in their centre in two patients with left pulmonary artery stenting without going into details [5]. This was not the case with the BeSmooth stents because the maximum achievable diameter without breaking the stent was 12–13 mm at the expense of an excessive and uncontrolled stent shortening. The stent-in-stent re-dilation approach did not have any impact on safely reaching larger stent inner diameters due to balloon rupture with loss of inflation pressure or uncontrolled stent fracture patterns at small balloon diameters.

The direct use of a single large-diameter balloon and/or a balloon longer than the stent tends to promote foreshortening of the stent during overexpansion. When the balloon is longer than the stent, the balloon can continue dilating at both distal and proximal non-covered extremities even when the stent has reached the maximal plateau diameter. The dog-boning phenomenon of the balloon will compress the extremities of the stent toward each other while the centre of the stent is expanding to its full diameter [13,14]. This will lead to excessive shortening and struts overlapping. On the other side, it may be discussed that fractures can be more easily achieved using less oversized balloons with higher inflation pressures rather than larger diameter balloons with lower pressures. However, in ideal clinical practice, stent re-dilation is achieved with gradual upsizing of the balloons keeping the balloon-to-waist ratio within the target ratio as low as possible [15,16]. It is unlikely that a balloon much bigger than the nominal stent diameter is immediately used, as the index vessel diameter in most cases will be slightly larger than the nominal stent diameter.

Alternative and novel therapies

For the aforementioned reasons, there was a development, in the past decade, of bioresorbable scaffolds or breakable paediatric-specific stents to offer a lower profile and wider potential diameters [17,18]. Unfortunately, these stents showed significant limitations and so far have not proved to be a good alternative [19]. Newer potential therapies are being evaluated for this unmet need in infants. A novel approach to this problem is using the newly developed BeGrow™ stent system by Bentley InnoMed with pre-determined breakage points to allow for expansion to larger diameters. The BeGrow™ stent is an L605 cobalt-chromium, a pre-mounted, balloon-expandable stent, compatible with a 4-Fr sheath and 0.014-inch guidewire, thereby allowing implantation in small vessels. The two first-in-man pulmonary artery stent implantations in a newborn with single-ventricle circulation and a toddler with biventricular circulation were reported as part of the ongoing licencing trial. It has been shown that the unique stent design allows post-dilation steps up to a diameter of 11.5 mm while maintaining radial force and uniform expansion with only minimal foreshortening. When exceeding a diameter of 11.5 mm, it has been only speculated that the spiral arrangement of the predetermined breaking points allows the stent to break in a controlled manner and maintain a residual radial force [20]. Longer in vivo follow-up will be needed to see how this stent performs clinically once breakage is achieved. Another novel approach to this problem is the new cobalt-chromium balloon-expandable Renata Minima stent with a unique cell design to allow for a wide range of stent diameters from 4 to 22 mm [21]. The stent comes pre-crimped onto a Minima delivery system balloon with an outer diameter comparable to a 4-Fr sheath and can be delivered directly over a 0.014 or 0.018-inch guidewire or via a 6-Fr sheath. This new stent was




Fig. 6 Three strut fractures of the BeSmooth $\varnothing 8 \times 57$ mm when expanded with a bare-metal 48 mm-long Optimus XXL stent mounted on an AltoSa-XL balloon $\varnothing 16$ mm (a). Note the full circular radial tear line within the balloon that was cut in half with subsequent loss of inflation pressure (b).

implanted in 22 different target vessels of six piglets. The animal study showed high implant success, predictable re-dilatation to adult diameters and favourable histopathology.^[21] Importantly, both bioresorbable and breakable strategies are designed to sacrifice future stent structural integrity to keep pace with growth. On the other side, the Minima stent is designed to provide lifelong vessel support. Further studies will be needed to determine if these differences are clinically relevant.

Limitations and strengths

Benchside tests of medical devices may not always predict clinical performance. We performed these tests *ex vivo* without supporting vessel walls. The mechanical properties of the stents alone will be the same, but these stents may behave differently *in vivo*. The *in vivo* duration of stent implantation may play a role in the susceptibility of the stent to fracture with balloon angioplasty. Fatigue longitudinal fractures resulting from chronic, cyclic loads applied over time can occur. Follow-up *in vivo* re-dilations may be undertaken on *in situ* fractured stents and the expansion patterns may be different. The use of a balloon shorter than or equal to the stent length may have offered differing results during Test 1. Ideally, we would have tested similar stents and repeated the measurements. However, we were limited to three samples of BeSmooth peripheral stents, which limits the statistical power and ability to generalise these findings. However, all reported tests were performed using the same testing equipment, in the same laboratory, and by the same personnel. Data were also collected meticulously during the same session to reduce any potential variation in test conditions. We believe that this study is noteworthy given that the data is novel. Our distinctive observations of this stent type during overdilation will offer practical information for end-users of this stent type.

Conclusion

In our benchmark setting and conditions, excessive stent shortening with overlapping struts, balloon rupture with loss of inflation pressure, or uncontrolled stent fracture patterns at small balloon diameters limit post-dilation of BeSmooth peripheral stents above a diameter of 13 mm. The sequential multiple-stage upsizing method of re-dilation and the straightforward or stepwise stent-in-stent re-dilation approaches did not have any impact on safely reaching larger stent inner diameters. These stents are not ideal candidates for off-label stent interventions in small children if re-expansion to adult vessel size is expected during follow-up. Efforts should be made to implant low-profile stents with adult diameter potential in children who will not require further cardiac surgery.

Acknowledgements. None.

Author Contributions. RH and SMM performed the benchside tests. RH collected data, performed direct and fluoroscopic measurements, designed illustrative material, and took the lead in writing and revising the entire manuscript. All authors discussed the results, have read and approved the final version of the manuscript.

Financial Support. This research received no specific grant from any funding agency, commercial, or not-for-profit sectors.

Conflicts of Interest. None.

References

1. Stanfill R, Nykanen DG, Osorio S, Whalen R, Burke RP, Zahn EM. Stent implantation is effective treatment of vascular stenosis in young infants with congenital heart disease: acute implantation and long-term follow-up results. *Catheter Cardiovasc Interv* 2008; 71: 831–841. DOI [10.1002/ccd.21526](https://doi.org/10.1002/ccd.21526).
2. Kudumula V, Noonan P, Taliotis D, Duke C. Implantation and preliminary follow-up of the Bard Valeo stent in pulmonary artery stenosis. *Catheter Cardiovasc Interv* 2014; 84: 197–203. DOI [10.1002/ccd.25443](https://doi.org/10.1002/ccd.25443).
3. Quandt D, Ramchandani B, Bhole V, et al. Initial experience with the cook formula balloon expandable stent in congenital heart disease. *Catheter Cardiovasc Interv* 2015; 85: 259–266. DOI [10.1002/ccd.25543](https://doi.org/10.1002/ccd.25543).
4. Travelli FC, Sullivan PM, Takao C, Ing FF. The Valeo stent: a pre-mounted, open-cell, large stent for use in small children with CHD. *Cardiol Young* 2016; 26: 1187–1193. DOI [10.1017/S10479511500219X](https://doi.org/10.1017/S10479511500219X).
5. van Kalsbeek RJ, Krings GJ, Molenschot MMC, Breur JMPJ. Early and mid-term outcomes of bare metal stenting in small children with recurrent aortic coarctation. *EuroIntervention* 2021; 16: e1281–e1287. DOI [10.4244/EIJ-D-19-00157](https://doi.org/10.4244/EIJ-D-19-00157).
6. Morray BH, McElhinney DB, Marshall AC, Porras D. Intentional fracture of maximally dilated balloon-expandable pulmonary artery stents using Ultra-high-pressure balloon angioplasty: a preliminary analysis. *Circ Cardiovasc Interv* 2016; 9: e003281. DOI [10.1161/CIRCINTERVENTIONS.115.003281](https://doi.org/10.1161/CIRCINTERVENTIONS.115.003281).
7. Sathanandam SK, Haddad LM, Subramanian S, Wright D, Philip R, Waller BR. Unzipping of small diameter stents: an *in vitro* study. *Catheter Cardiovasc Interv* 2015; 85: 249–258. DOI [10.1002/ccd.25596](https://doi.org/10.1002/ccd.25596).
8. McMahon CJ, El-Said HG, Grifka RG, Fraley JK, Nihill MR, Mullins CE. Redilation of endovascular stents in congenital heart disease: factors implicated in the development of restenosis and neointimal proliferation. *J Am Coll Cardiol* 2001; 38: 521–526. DOI [10.1016/s0735-1097\(01\)01406-1](https://doi.org/10.1016/s0735-1097(01)01406-1).
9. Boe BA, Zampi JD, Schumacher KR, Yu S, Armstrong AK. The use and outcomes of small, medium and large pre-mounted stents in pediatric and congenital heart disease. *Pediatr Cardiol* 2016; 37: 1525–1533. DOI [10.1007/s00246-016-1466-8](https://doi.org/10.1007/s00246-016-1466-8).
10. Ing FF, Khan A, Kobayashi D, Hagler DJ, Forbes TJ. Pulmonary artery stents in the recent era: immediate and intermediate follow-up. *Catheter Cardiovasc Interv* 2014; 84: 1123–1130. DOI [10.1002/ccd.25567](https://doi.org/10.1002/ccd.25567).

11. Agnoletti G, Marini D, Ou P, Vandrell MC, Boudjemline Y, Bonnet D. Cheatham platinum (CP) and Palmaz stents for cardiac and vascular lesions treatment in patients with congenital heart disease. *EuroIntervention* 2009; 4: 620–625. DOI [10.4244/eijv4i5a104](https://doi.org/10.4244/eijv4i5a104).
12. Krasemann T, Kruit MN, van der Mark AE, Zeggelaar M, Dalinghaus M, van Beynum IM. Dilating and fracturing side struts of open cell stents frequently used in pediatric cardiac interventions-an in vitro study. *J Interv Cardiol* 2018; 31: 834–840. DOI [10.1111/joic.12549](https://doi.org/10.1111/joic.12549).
13. Peters B, Ewert P, Berger F. The role of stents in the treatment of congenital heart disease: current status and future perspectives. *Ann Pediatr Cardiol* 2009; 2: 3–23. DOI [10.4103/0974-2069.52802](https://doi.org/10.4103/0974-2069.52802).
14. Wong J, Backer E, Keenan JC, Dincer HE, Cho RJ. To investigate the effect of targeted overdilation in balloon-expandable stents. *Med Devices (Auckl)* 2021; 14: 321–325. DOI [10.2147/MDER.S336933](https://doi.org/10.2147/MDER.S336933).
15. Danon S, Gray RG, Crystal MA, et al. Expansion characteristics of stents used in congenital heart disease: serial dilation offers improved expansion potential compared to direct dilation: results from a pediatric interventional cardiology early career society (PICES) investigation. *Congenit Heart Dis* 2016; 11: 741–750. DOI [10.1111/chd.12399](https://doi.org/10.1111/chd.12399).
16. Fujimoto K, Fujii T, Hata Y, et al. Stent unzipping using an ultra-high-pressure balloon: in vitro and animal experiments. *Heart Vessels* 2018; 33: 239–245. DOI [10.1007/s00380-017-1060-x](https://doi.org/10.1007/s00380-017-1060-x).
17. Grohmann J, Sigler M, Siepe M, Stiller B. A new breakable stent for recoarctation in early infancy: preliminary clinical experience. *Catheter Cardiovasc Interv* 2016; 87: E143–50. DOI [10.1002/ccd.26393](https://doi.org/10.1002/ccd.26393).
18. Ewert P, Peters B, Nagdyman N, Miera O, Kühne T, Berger F. Early and mid-term results with the Growth Stent—a possible concept for transcatheter treatment of aortic coarctation from infancy to adulthood by stent implantation? *Catheter Cardiovasc Interv* 2008; 71: 120–126. DOI [10.1002/ccd.21397](https://doi.org/10.1002/ccd.21397).
19. Haddad RN, Adel Hassan A, Al Soufi M, Kasem M. A word of caution: early failure of Magmaris® bioresorbable stent after pulmonary artery stenting. *Catheter Cardiovasc Interv* 2022; 101: 131–134. DOI [10.1002/ccd.30487](https://doi.org/10.1002/ccd.30487).
20. Quandt D, Knirsch W, Michel-Behnke I, et al. First-in-man pulmonary artery stenting in children using the Bentley® BeGrow™ stent system for newborns and infants. *Int J Cardiol* 2019; 276: 107–109. DOI [10.1016/j.ijcard.2018.11.029](https://doi.org/10.1016/j.ijcard.2018.11.029).
21. Zahn EM, Abbott E, Tailor N, Sathanandam S, Armer D. Preliminary testing and evaluation of the renata minima stent, an infant stent capable of achieving adult dimensions. *Catheter Cardiovasc Interv* 2021; 98: 117–127. DOI [10.1002/ccd.29706](https://doi.org/10.1002/ccd.29706).